

# Henoch-Schönlein purpura nephritis in children: incidence, pathogenesis and management

Jun-Yi Chen, Jian-Hua Mao

Hangzhou, China

**Background:** Henoch-Schönlein purpura (HSP) is one of the most common vasculitides in children. It is manifested by skin purpura, arthritis, abdominal pain, renal involvement, etc. Typically, HSP is considered to be self-limiting, although renal involvement (HSP purpura nephritis, HSPN) is the principal cause of morbidity from this disease. For this reason, it is important to clarify the mechanism of onset and clinical manifestations of HSPN and to ascertain the most appropriate treatment for HSPN. In this article, we review the updated pathophysiology and treatment strategies for HSPN.

**Data sources:** We searched databases including PubMed, Elsevier and Wanfang for the following key words: Henoch-Schönlein purpura, nephritis, mechanism and treatment, and we selected those publications written in English that we judged to be relevant to the topic of this review.

**Results:** Based on the data present in the literature, we reviewed the following topics: 1) the possible pathogenesis of HSPN: several studies suggest that immunoglobulin A immune complexes deposit in the mesangium and induce renal injury; 2) multiple-drug treatment for HSPN: although there have been few evidence-based treatment strategies for HSPN, several studies have suggested that immunosuppressive drugs and multiple drug combination therapy were effective in ameliorating proteinuria and histological severity.

**Conclusions:** HSPN is a severe disease of childhood. To better understand this disease, detailed investigations into the pathogenesis of HSPN and prospective randomized controlled treatment studies on children with severe HSPN are needed.

*World J Pediatr 2015;11(1):29-34*

**Author Affiliations:** Department of Nephrology, Children's Hospital, Zhejiang University School of Medicine, Hangzhou 310003, China (Chen JY, Mao JH)

**Corresponding Author:** Jian-Hua Mao, PhD, Department of Nephrology, Children's Hospital, Zhejiang University School of Medicine, Hangzhou 310003, China (Tel: 86-571-87061007; Fax: 86-571-87033296; Email: maojh88@126.com)

doi: 10.1007/s12519-014-0534-5

©Children's Hospital, Zhejiang University School of Medicine, China and Springer-Verlag Berlin Heidelberg 2014. All rights reserved.

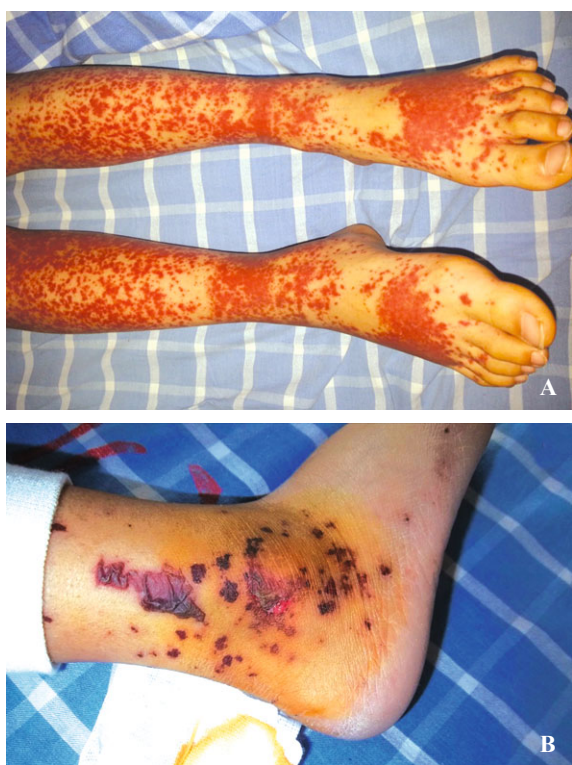**Key words:** Henoch-Schönlein purpura; immunosuppressive drug; nephritis; pathogenesis; treatment

## Introduction

Henoch-Schönlein purpura (HSP) was first described more than 200 years ago by Heberdon who treated two boys with purpuric rash, arthralgia and abdominal pain. Since then, thousands of articles on HSP have been published. Cutaneous purpura typically appears on the legs and buttocks, but it may also be observed on the arms, face and trunk. Generally, the prognosis of HSP in children is favorable, but there are severe complications, one of which is renal involvement. Up to 50% of pediatric patients develop nephritis within 4 to 6 weeks of the initial presentation. Most patients with HSP nephritis (HSPN) have a mild form of the disease, presenting with only hematuria and/or low-grade proteinuria, and have a good chance of recovery. However, a small percentage of patients present with nephrotic syndrome or renal function impairment. Therefore, it is important to clarify the mechanism of onset and the clinical manifestations and to ascertain the most appropriate treatment of HSPN. The main goal of this review article is to understand the pathogenesis of HSPN and its appropriate therapy.

## Incidence

HSP is the most common systemic small-vessel vasculitis in children. Because numerous systemic small vessels are involved, the multiple manifestations of the disease include nonthrombocytopenic purpuric rash (Fig. 1), non-deforming arthritis, gastrointestinal involvement and nephritis. It has been reported that 6 to 24 per 100 000 children younger than 17 years will develop HSP, depending on the ethnic background of the child.<sup>[1]</sup> In Asia, the incidence is as high as approximately 70 cases/100 000 children per year.<sup>[1]</sup> For the majority of



**Fig. 1.** Skin lesions in children with Henoch-Schönlein purpura. Petechiae and palpable purpurae are the most common skin lesions (A), but erythematous, macular, urticarial or even bullous rashes (B) are observed occasionally (Department of Nephrology, Children's Hospital, Zhejiang University School of Medicine).

affected children, the outcome of HSP is excellent, with resolution of symptoms and signs within several days or months. The long-term morbidity of HSP is related to the degree of renal involvement. Previous studies<sup>[2,3]</sup> have reported that up to 30%-50% of pediatric patients with HSP either have or will develop hematuria and/or proteinuria as symptoms of nephritis within 4 to 6 weeks of the initial presentation, both of which are typically minor in extent or self-limited. However, approximately 20% of HSPN patients (7% of all HSP cases) will develop either a nephritis or nephrotic syndrome. In specialized centers, the proportion of children with HSPN progressing to renal failure or end-stage renal disease ranges from 1% to 7%.<sup>[1,4-9]</sup>

### Pathophysiology

Although it is known that HSP is a small vessel leucocytoclastic vasculitis, its pathogenetic mechanisms are not yet fully identified. Researchers<sup>[10-13]</sup> have found elevations in the serum levels of immunoglobulin (Ig) A, IgA-containing circulating immune complexes and IgA rheumatoid factors in patients with HSP. Therefore, it

is generally believed that HSP is an immune complex-mediated disease. Because HSP is frequently reported to follow respiratory tract infections, a variety of viral and bacterial pathogens have been implicated as triggers of the disease.<sup>[14]</sup>

It has been reported that all patients with HSP have small molecular mass IgA1-containing circulating immune complexes, but only those with HSPN have additional large molecular mass IgA1-IgG-containing circulating immune complexes.<sup>[15]</sup> The IgA1 molecule has a hinge region containing up to six O-linked glycan chains<sup>[16,17]</sup> consisting of N-acetylgalactosamine, usually with an attached  $\beta$ 1,3-linked galactose.<sup>[18,19]</sup> It has been reported that in patients with HSPN, the activity of  $\beta$ 1,3-galactosyltransferase in peripheral B cells is reduced, leading to a lack of terminal  $\beta$ 1,3-galactosyl residues in the hinge region of IgA1.<sup>[20-22]</sup> The primary defect leading to the production of such abnormally glycosylated IgA1 is probably heritable.<sup>[23]</sup> These aberrantly glycosylated IgA1 molecules have been shown to form immune complexes with IgG antibodies specific for galactose-deficient IgA1, thereby inhibiting the binding of the IgA molecules to hepatic receptors and avoiding their internalization and degradation by hepatic cells.<sup>[24,25]</sup> This formation results in an increased amount of IgA immune complexes in circulation. The complexes may then deposit in renal mesangial areas and activate the complement system by the alternative or lectin pathways,<sup>[26]</sup> which play a major role in the pathophysiology of this disease.<sup>[27]</sup> Further, after depositing in the mesangium, the galactose-deficient IgA1 immune complexes activate mesangial cells. This results in the proliferation of cells such as macrophages and lymphocytes and the production of inflammatory and profibrogenic cytokines and chemokines, which play a pivotal role in mesangial cell proliferation, matrix expansion and inflammatory cell recruitment.<sup>[28]</sup>

There are also other possible pathogenetic mechanisms of HSPN. Because throat cultures positive for group A beta-hemolytic *streptococcus* have been found in 20%-30% of patients with HSPN,<sup>[2,3]</sup> it is thought that nephritis-associated plasmin receptor, a group A *streptococcal* antigen, may also be responsible for some of cases of HSPN.<sup>[29]</sup> In addition, eosinophil activation<sup>[30-32]</sup> and renal expression of alpha-smooth muscle actin<sup>[33]</sup> have been reported to play a role in the pathogenesis of HSPN.

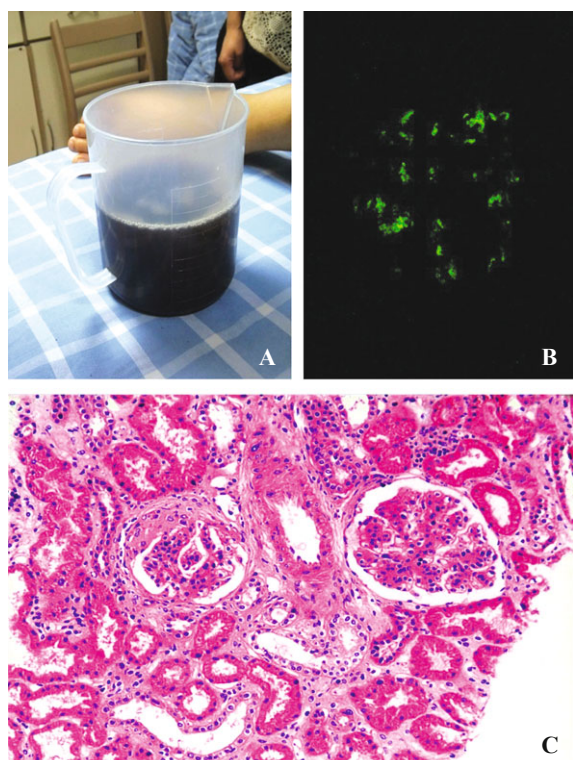
### Pathology

The International Study of Kidney Disease in Children (ISKDC) classification is widely used for patients

with HSPN.<sup>[7]</sup> According to this classification, HSPN is graded as follows: grade I: minimal glomerular abnormalities; grade II: mesangial proliferation without crescents or sclerosing lesions; grade III: focal segmental (IIIa) or diffuse (IIIb) mesangial proliferation with <50% crescents or sclerosing lesions; grade IV: mesangial proliferation with 50%-75% crescents or sclerosing lesions; grade V: mesangial proliferation with >75% crescents or sclerosing lesions; and grade VI: membranoproliferative-like lesions (Fig. 2).

### Management strategies

For most patients with HSPN, the typical urinary abnormalities are microscopic hematuria and/or proteinuria, but a smaller percentage of patients have macroscopic hematuria. Approximately 21% of children with HSPN develop nephritic and/or nephrotic syndrome. Given the large proportion of patients with a favorable prognosis and the unpredictable clinical course among individual patients, it is sometimes difficult to make an appropriate treatment decision.



**Fig. 2.** Renal involvement in children with Henoch-Schönlein purpura. **A:** Gross hematuria; **B:** Immunohistochemical staining demonstrates the granular deposition of immunoglobulin A in the mesangium of the affected glomerulus (original magnification  $\times 200$ ); **C:** Mesangial cell proliferation is observed in both glomeruli, and crescent formation is observed in the glomerulus on the left (original magnification  $\times 200$ ) (Department of Nephrology, Children's Hospital, Zhejiang University School of Medicine).

In addition, few evidence-based treatment studies are available, even for severe cases. The current therapeutic approach to HSPN is based on the assumed pathophysiology and published case studies. Because the pathophysiology of HSPN appears to be similar or identical to that of IgA nephropathy (IgAN), the results from studies of patients with IgAN are also a valuable source of information for developing potential treatment options.

The Kidney Disease Improving Global Outcome (KDIGO) guidelines<sup>[34]</sup> recommend that children with HSPN with persistent proteinuria, defined as  $>0.5$ - $1$  g/d per  $1.73$  m<sup>2</sup>, should be treated with angiotensin converting enzyme inhibitors (ACE-I) or angiotensin receptor blockers (ARBs). It is recommended that after a trial of ACE-I or ARBs, those with persistent proteinuria, defined as  $>1$  g/d per  $1.73$  m<sup>2</sup>, and glomerular filtration rate  $>50$  mL/min per  $1.73$  m<sup>2</sup>, should be treated the same as patients with IgAN, with a 6-month course of corticosteroid therapy. According to the KDIGO guidelines, those with crescentic HSP with nephrotic syndrome and/or deteriorating kidney function should be treated the same as patients with crescentic IgAN. Some experts<sup>[35]</sup> believe that the therapy recommended in the KDIGO guidelines may lead to under-treatment because there is a possibility that an acute and potentially aggressive glomerular inflammation could remain untreated or that its immunosuppressive treatment could be delayed for several months. Although there is no consensus for the treatment of patients with HSPN, patients with minimal renal symptoms such as microhematuria, mild proteinuria and normal renal function should be followed to detect any change that could eventually lead to a kidney biopsy and a decision to treat.

For other patients, a wide variety of immunosuppressive agents (steroids, cyclophosphamide, azathioprin and calcineurin inhibitors) has been used for treatment. Park et al<sup>[36]</sup> retrospectively analyzed 29 patients with HSPN and nephrotic-range proteinuria treated with cyclosporin A and demonstrated that cyclosporin A is a very effective and safe treatment. Du et al<sup>[37]</sup> treated 12 patients with HSPN with mycophenolate mofetil (MMF), and in all patients, proteinuria resolved, normal renal function resumed and no relapse was noted. One small randomized controlled trial of 17 children with ISKDC grade I to III HSPN compared 1 year of treatment with MMF to treatment with azathioprine. All children received prednisone for 6 months but were not treated with ACE-I. Proteinuria resolved in all 9 children treated with MMF, and six of eight children treated with azathioprine. Seven of the 9 patients treated with MMF and 5 of the 8 patients treated with azathioprine showed regression of histological changes at 1 year.<sup>[38]</sup> Although

these data are compelling, they are insufficient to draw definitive conclusions about the value of MMF for treating HSPN in children. A recent prospective and controlled study<sup>[39]</sup> in China suggested that triptolide, the major active component of the Chinese traditional medicine *Tripterygium wilfordii* hook f, is effective for treating moderately severe HSPN. In that study, 56 children with HSPN manifested by nephrotic-range proteinuria with normal kidney function and <50% crescents or sclerosing lesions on biopsy were recruited. Forty-two children received triptolide at a dose of 1 mg/kg per day combined with prednisone at a dose of 2 mg/kg per day over a medium-to-long-term therapy course of 6 to 9 months, and 14 children received prednisone therapy alone. In this study, short-term remission was observed in 95% of the patients in the treatment group and 72% of the patients in the control group, demonstrating that triptolide is effective in relieving the short-term symptoms in children with moderately severe HSPN, although the long-term effects of triptolide need to be observed further. Another immunosuppressive drug, rituximab (RTX), a therapeutic monoclonal antibody against the surface antigen CD20 expressed by B cells, is thought to reduce circulating IgA and could be an attractive intervention for patients with refractory HSP.<sup>[40]</sup> Donnithorne et al<sup>[41]</sup> treated a 17-year-old white boy, who had hypertension, hematuria and hypoalbuminemia (3.1 g/dL), with 1000 mg RTX infusions twice 2 weeks apart. His proteinuria improved within 3 weeks of his first RTX infusion.

And in those with rapidly progressive glomerulonephritis, multiple-drug therapies include methylprednisolone followed by prednisone, methylprednisolone combined with urokinase pulse therapy with or without mizoribine, and corticosteroid with cyclophosphamide, azathioprine or mizoribine,<sup>[42-44]</sup> have been shown to be useful. However, no enough evidence has shown that immunosuppression drug or multiple-drug is more effective.

There are also several reports<sup>[45,46]</sup> suggesting that plasmapheresis is an effective way to improve the prognosis of patients with rapidly progressive HSPN because plasmapheresis can remove circulating complexes and inflammatory and procoagulatory substances. Donghi et al<sup>[47]</sup> reported 2 cases of adult HSP with an unusually severe evolution. In both patients, the disease was refractory to common immunosuppression with systemic corticosteroids (oral and pulse) and additive steroid-sparing immunosuppressive drugs. Only after the introduction of plasmapheresis did both patients show a dramatic improvement with rapid and nearly complete healing. Fourteen HSPN children, who had at least grade III

nephritis on renal biopsy, received plasmapheresis (90 mL/kg per session) for 2 weeks. It was reported that plasmapheresis may have a beneficial effect on severe HSN without the potential side effects of immunosuppressive therapies.<sup>[48]</sup>

Some adjuvant therapies such as immunoglobulin, anticoagulants, antiplatelet drugs and vitamins have also been used in combination with immunosuppressive agents, but the reviews do not recommend these adjuvant treatments.<sup>[49]</sup> Because acute episodes of HSPN are often triggered by an upper respiratory tract infection, tonsillectomy has been found to be an effective and useful therapy for some children with severe HSPN because it is thought that tonsillectomy might remove the source of chronic bacterial infection.<sup>[50,51]</sup> When tonsillectomy has been used to treat HSPN, however, it is usually used in combination with immunosuppressive agents.

## Conclusions

HSP is one of the most common vasculitides of children and is considered to be self-limiting. One manifestation of HSP that can result in lifelong problems is renal involvement. Although the prognosis for the majority of children with HSPN is good, 1%-7% of patients with HSPN may progress to renal failure or end-stage renal disease. Although the pathogenetic mechanisms of HSPN have not been fully delineated, galactose-deficient IgA1 is thought to play an important role. Various immunosuppressive agents and corticosteroids, with or without adjuvant therapies, have been used to treat HSPN, and they have been found to be effective in some cases and in small-sample patient studies. Prospective randomized controlled treatment studies are needed, especially in children with severe HSPN defined by acute nephritic syndrome, nephrotic syndrome with or without reduced kidney function and >50% crescents or sclerosing lesions on biopsy.

**Funding:** This project was supported by grants from the National Natural Science Foundation of China (Grant Nos. 81270792, 81470939 and 81170664), State "1025" Science and Technology Support Project (2012BA103B02), the Research Fund for the Doctoral Program of Higher Education of China (20120101110018).

**Ethical approval:** Not needed.

**Competing interest:** None.

**Contributors:** Both Chen JY and Mao JH contributed equally to the design and interpretation of the study and further draft. Chen JY wrote the first version of the article under the supervision of Mao JH.

## References

- Gardner-Medwin JM, Dolezalova P, Cummins C, Southwood TR. Incidence of Henoch-Schönlein purpura, Kawasaki disease, and rare vasculitides in children of different ethnic origins. *Lancet* 2002;360:1197-1202.
- Calviño MC, Llorca J, García-Porrúa C, Fernández-Iglesias JL, Rodríguez-Ledo P, González-Gay MA. Henoch-Schönlein purpura in children from northwestern Spain: a 20-year epidemiologic and clinical study. *Medicine (Baltimore)* 2001;80:279-290.
- Saulsbury FT. Henoch-Schönlein purpura in children. Report of 100 patients and review of the literature. *Medicine (Baltimore)* 1999;78:395-409.
- Nielsen HE. Epidemiology of Schönlein-Henoch purpura. *Acta Paediatr Scand* 1988;77:125-131.
- Stewart M, Savage JM, Bell B, McCord B. Long term renal prognosis of Henoch-Schönlein purpura in an unselected childhood population. *Eur J Pediatr* 1988;147:113-115.
- Yoshikawa N, Ito H, Yoshiya K, Nakahara C, Yoshiara S, Hasegawa O, et al. Henoch-Schoenlein nephritis and IgA nephropathy in children: a comparison of clinical course. *Clin Nephrol* 1987;27:233-237.
- Counahan R, Winterborn MH, White RH, Heaton JM, Meadow SR, Bluett NH, et al. Prognosis of Henoch-Schönlein nephritis in children. *Br Med J* 1977;2:11-14.
- Bunchman TE, Mauer SM, Sibley RK, Vernier RL. Anaphylactoid purpura: characteristics of 16 patients who progressed to renal failure. *Pediatr Nephrol* 1988;2:393-397.
- Saulsbury FT. Epidemiology of Henoch-Schönlein purpura. *Cleve Clin J Med* 2002;69 Suppl 2:SII87-SII89.
- Davin JC, Ten Berge IJ, Weening JJ. What is the difference between IgA nephropathy and Henoch-Schönlein purpura nephritis? *Kidney Int* 2001;59:823-834.
- Knight JF. The rheumatic poison: a survey of some published investigations of the immunopathogenesis of Henoch-Schönlein purpura. *Pediatr Nephrol* 1990;4:533-541.
- Saulsbury FT. IgA rheumatoid factor in Henoch-Schönlein purpura. *J Pediatr* 1986;108:71-76.
- Fervenza FC. Henoch-Schonlein purpura nephritis. *Int J Dermatol* 2003;42:170-177.
- Pohl M. Henoch-Schönlein purpura nephritis. *Pediatr Nephrol* 2014 Apr 15. [Epub ahead of print]
- Levinsky RJ, Barratt TM. IgA immune complexes in Henoch-Schönlein purpura. *Lancet* 1979;2:1100-1103.
- Renfrow MB, Mackay CL, Chalmers MJ, Julian BA, Mestecky J, Kilian M, et al. Analysis of O-glycan heterogeneity in IgA1 myeloma proteins by Fourier transform ion cyclotron resonance mass spectrometry: implications for IgA nephropathy. *Anal Bioanal Chem* 2007;389:1397-1407.
- Tarelli E, Smith AC, Hendry BM, Challacombe SJ, Pouria S. Human serum IgA1 is substituted with up to six O-glycans as shown by matrix assisted laser desorption ionisation time-of-flight mass spectrometry. *Carbohydr Res* 2004;339:2329-2335.
- Field MC, Dwek RA, Edge CJ, Rademacher TW. O-linked oligosaccharides from human serum immunoglobulin A1. *Biochem Soc Trans* 1989;17:1034-1035.
- Baenziger J, Kornfeld S. Structure of the carbohydrate units of IgA1 immunoglobulin. II. Structure of the O-glycosidically linked oligosaccharide units. *J Biol Chem* 1974;249:7270-7281.
- Novak J, Moldoveanu Z, Renfrow MB, Yanagihara T, Suzuki H, Raska M, et al. IgA nephropathy and Henoch-Schoenlein purpura nephritis: aberrant glycosylation of IgA1, formation of IgA1-containing immune complexes, and activation of mesangial cells. *Contrib Nephrol* 2007;157:134-138.
- Lau KK, Wyatt RJ, Moldoveanu Z, Tomana M, Julian BA, Hogg RJ, et al. Serum levels of galactose-deficient IgA in children with IgA nephropathy and enoch-Schönlein purpura. *Pediatr Nephrol* 2007;22:2067-2072.
- Allen AC, Willis FR, Beattie TJ, Feehally J. Abnormal IgA glycosylation in Henoch-Schönlein purpura restricted to patients with clinical nephritis. *Nephrol Dial Transplant* 1998;13:930-934.
- Gharavi AG, Moldoveanu Z, Wyatt RJ, Barker CV, Woodford SY, Lifton RP, et al. Aberrant IgA1 glycosylation is inherited in familial and sporadic IgA nephropathy. *J Am Soc Nephrol* 2008;19:1008-1014.
- Tomana M, Matousovic K, Julian BA, Radl J, Konecny K, Mestecky J. Galactose-deficient IgA1 in sera of IgA nephropathy patients is present in complexes with IgG. *Kidney Int* 1997;52:509-516.
- Novak J, Vu HL, Novak L, Julian BA, Mestecky J, Tomana M, et al. Interactions of human mesangial cells with IgA and IgA-containing immune complexes. *Kidney Int* 2002;62:465-475.
- Oortwijn BD, Eijgenraam JW, Rastaldi MP, Roos A, Daha MR, van Kooten C. The role of secretory IgA and complement in IgA nephropathy. *Semin Nephrol* 2008;28:58-65.
- Wyatt RJ, Kanayama Y, Julian BA, Negoro N, Sugimoto S, Hudson EC, et al. Complement activation in IgA nephropathy. *Kidney Int* 1987;31:1019-1023.
- Moura IC, Benhamou M, Launay P, Vrtovnik F, Blank U, Monteiro RC, et al. The glomerular response to IgA deposition in IgA nephropathy. *Semin Nephrol* 2008;28:88-95.
- Masuda M, Nakanishi K, Yoshizawa N, Iijima K, Yoshikawa N. Group A streptococcal antigen in the glomeruli of children with Henoch-Schönlein nephritis. *Am J Kidney Dis* 2003;41:366-370.
- Chen Y, Zhou JH, Wu HS, Wang HW. Role of mast cells and eosinophil cationic protein in the pathogenesis of Henoch-Schönlein purpura nephritis. *Zhonghua Er Ke Za Zhi* 2006;44:407-410. [In Chinese]
- Kawasaki Y, Hosoya M, Suzuki H. Possible pathogenic role of interleukin-5 and eosino cationic protein in Henoch-Schönlein purpura nephritis. *Pediatr Int* 2005;47:512-517.
- Namgoong MK, Lim BK, Kim JS. Eosinophil cationic protein in Henoch-Schönlein purpura and in IgA nephropathy. *Pediatr Nephrol* 1997;11:703-706.
- Kawasaki Y, Imaizumi T, Matsuura H, Ohara S, Takano K, Suyama K, et al. Renal expression of alpha-smooth muscle actin and c-Met in children with Henoch-Schönlein purpura nephritis. *Pediatr Nephrol* 2008;23:913-919.
- Chapter 11: Henoch-Schönlein purpura nephritis. *Kidney Int Suppl* (2011) 2012;2:218-220.
- Davin JC, Coppo R. Pitfalls in recommending evidence-based guidelines for a protean disease like Henoch-Schönlein purpura nephritis. *Pediatr Nephrol* 2013;28:1897-1903.
- Park JM, Won SC, Shin JI, Yim H, Pai KS. Cyclosporin A therapy for Henoch-Schönlein nephritis with nephrotic-range proteinuria. *Pediatr Nephrol* 2011;26:411-417.
- Du Y, Hou L, Zhao C, Han M, Wu Y. Treatment of children with Henoch-Schönlein purpura nephritis with mycophenolate mofetil. *Pediatr Nephrol* 2012;27:765-771.
- Fuentes Y, Valverde S, Valesquez-Jones L. Comparison of azathioprine vs mofetil mycophenolate for Henoch-Schönlein nephritis treatment (abstract). *Pediatr Nephrol* 2010;25:1802.

- 39 Wu L, Mao J, Jin X, Fu H, Shen H, Wang J, et al. Efficacy of triptolide for children with moderately severe Henoch-Schönlein purpura nephritis presenting with nephrotic range proteinuria: a prospective and controlled study in China. *Biomed Res Int* 2013;2013:292865.
- 40 Pillebout E, Rocha F, Fardet L, Rybojad M, Verine J, Glotz D. Successful outcome using rituximab as the only immunomodulation in Henoch-Schönlein purpura: case report. *Nephrol Dial Transplant* 2011;26:2044-2046.
- 41 Donnithorne KJ, Atkinson TP, Hinze CH, Nogueira JB, Saeed SA, Askenazi DJ, et al. Rituximab therapy for severe refractory chronic Henoch-Schönlein purpura. *J Pediatr* 2009;155:136-139.
- 42 Flynn JT, Smoyer WE, Bunchman TE, Kershaw DB, Sedman AB. Treatment of Henoch-Schönlein Purpura glomerulonephritis in children with high-dose corticosteroids plus oral cyclophosphamide. *Am J Nephrol* 2001;21:128-133.
- 43 Kawasaki Y, Suyama K, Hashimoto K, Hosoya M. Methylprednisolone pulse plus mizoribine in children with Henoch-Schoenlein purpura nephritis. *Clin Rheumatol* 2011;30:529-535.
- 44 Kawasaki Y, Suzuki J, Suzuki H. Efficacy of methylprednisolone and urokinase pulse therapy combined with or without cyclophosphamide in severe Henoch-Schoenlein nephritis: a clinical and histopathological study. *Nephrol Dial Transplant* 2004;19:858-864.
- 45 Kawasaki Y, Suzuki J, Murai M, Takahashi A, Isome M, Nozawa R, et al. Plasmapheresis therapy for rapidly progressive Henoch-Schönlein nephritis. *Pediatr Nephrol* 2004;19:920-923.
- 46 Davin JC. Henoch-Schönlein purpura nephritis: pathophysiology, treatment, and future strategy. *Clin J Am Soc Nephrol* 2011;6:679-689.
- 47 Donghi D, Schanz U, Sahrbacher U, Recher M, Trüeb RM, Müllhaupt B, et al. Life-threatening or organ-impairing Henoch-Schönlein purpura: plasmapheresis may save lives and limit organ damage. *Dermatology* 2009;219:167-170.
- 48 Shenoy M, Ognjanovic MV, Coulthard MG. Treating severe Henoch-Schönlein and IgA nephritis with plasmapheresis alone. *Pediatr Nephrol* 2007;22:1167-1171.
- 49 Zaffanello M, Brugnara M, Franchini M, Fanos V. Adjuvant treatments for Henoch-Schönlein purpura nephritis in children: A systematic review. *Curr Ther Res Clin Exp* 2009;70:254-265.
- 50 Kawasaki Y, Suyama K, Matsumoto A, Takano K, Hashimoto K, Suzuki S, et al. Efficacy of tonsillectomy plus methylprednisolone pulse therapy for a child with Henoch-Schoenlein purpura nephritis. *Tohoku J Exp Med* 2007;211:291-295.
- 51 Kanai H, Sawanobori E, Kobayashi A, Matsushita K, Sugita K, Higashida K. Early treatment with methylprednisolone pulse therapy combined with tonsillectomy for heavy proteinuric henoch-schönlein purpura nephritis in children. *Nephron Extra* 2011;1:101-111.

*Received May 31, 2014*

*Accepted after revision September 12, 2014*