

The frequency of histologic lesion variability of the duodenal mucosa in children with celiac disease

Kaushal Kishor Prasad, Babu Ram Thapa, Chander Kanwal Nain, Kartar Singh

Chandigarh, India

Background: Celiac disease (CD) may cause changes throughout the gastrointestinal tract. Patchy distribution of duodenal mucosal lesions has been described in adults as well as in children. This study aimed to verify the concept and to evaluate the frequency of histologic lesion variability of the duodenal mucosa in Indian children with CD.

Methods: We enrolled 67 children prospectively who underwent upper gastrointestinal endoscopy because of positive tissue transglutaminase antibodies and biopsy as the final evaluation for suspected CD. Four biopsies were taken from the descending duodenum distal to the papilla, and duodenal bulb. The histologic lesions were classified according to the Oberhuber classification with modification proposed by our group.

Results: Forty-three CD children (64.2%) had a "mixed" type 3 lesion characterized by a different degree of villous atrophy at different biopsy sites. Eight children (11.9%) showed two different types of histologic lesions in the same patient at different biopsy sites. The overall variability of histologic lesion (variability in the grade of villous atrophy [type 3a, 3b, or 3c], and coexistence of villous atrophy and type 2 lesion) was seen in 51 (76.1%) of the CD patients.

Conclusions: Children with CD show a high frequency of variability of histologic lesions. Therefore, multiple endoscopic biopsy specimens should be obtained not only from the distal duodenum but also from the bulb.

World J Pediatr 2010;6(1):60-64

Key words: celiac disease; duodenum; histologic lesion; villous atrophy

Introduction

Celiac disease (CD) is a permanent condition of gluten intolerance in which exposure to gluten results in characteristic pathologic changes in the gastrointestinal tract, most notably in the small intestine, where the histologic features include villous atrophy (VA), crypt hyperplasia, mononuclear cell infiltration of the lamina propria, and a pronounced intraepithelial lymphocytosis. The diagnosis of CD requires recognition of characteristic pathologic changes in an intestinal biopsy, accompanied by clinical and/or histologic improvement on a gluten-free diet.^[1] Positive serologic tests are supportive of the diagnosis but not necessary.^[1] The gluten sensitivity can produce a spectrum of morphologic abnormalities within the proximal small bowel mucosa, ranging from architecturally normal villi to complete flattening.^[2] The development of CD is a dynamic process whereby mucosal damage to the small intestine develops in three subsequent phases: (a) infiltrative phase, characterized solely by an increased number of intraepithelial lymphocytes (IEL); (b) hyperplastic phase, characterized by crypt hypertrophy; and (c) destructive phase, which is characterized by progressive VA ultimately leading to the flattening of the mucosa.^[3] It is generally believed that in CD, mucosal lesions may have a patchy distribution. At the diagnosis of CD, patchy distribution of duodenal VA has been described in adults.^[4,5] In addition, recent report has described patchy VA of the duodenal mucosa in 16 CD children, 13 at diagnosis and the other 3 during gluten challenge.^[6]

The aim of this study was to verify this concept and evaluate the frequency of histologic lesion variability of the duodenal mucosa in Indian children with CD in whom multiple endoscopic biopsies were obtained.

Author Affiliations: Department of Superspeciality of Gastroenterology, Post Graduate Institute of Medical Education and Research, Chandigarh (UT) - 160 012, India (Prasad KK, Thapa BR, Nain CK, Singh K)

Corresponding Author: Kaushal Kishor Prasad, MD, PDC, Division of GE Histopathology, Department of Superspeciality of Gastroenterology, Post Graduate Institute of Medical Education and Research, Chandigarh (UT) -160 012, India (Tel: +91-172-2756604; Fax: +91-172-2744401, 2744450; Email: kaushalkp10@hotmail.com)

doi:10.1007/s12519-010-0008-3

©2010, World J Pediatr. All rights reserved.

Methods

Patients and sampling

In year 2006 over the period of 4 and half months, we studied 67 children prospectively, who underwent upper gastrointestinal endoscopy because of positive tissue transglutaminase (tTG) antibodies and biopsy as the final evaluation for suspected CD. All the children consumed a normal gluten-containing diet during the study. The diagnosis of CD was made based upon clinical presentation, histologic findings, and serological data. For patients diagnosed with CD, a gluten-free diet was prescribed. In our area, CD has a prevalence of about 1:120 in the pediatric population^[7] and in our institution we diagnose 4-5 new cases of CD per week, most of whom are patients referred to our celiac disease clinic at the Postgraduate Institute of Medical Education & Research, Chandigarh (India). After written informed consent was obtained from their parents, all children underwent upper gastrointestinal endoscopy after intravenous anesthesia (ketamine 1 mg/kg) using a video endoscope (Olympus GIF-160). At the end of the procedure, multiple duodenal biopsy specimens ($n=4-6$) were taken with standard needle biopsy forceps from the descending duodenum distal to the papilla of Vater (D_2), and duodenal bulb (B). Biopsies were carefully orientated with the luminal side uppermost; biopsy specimens were disposed on filter paper and fixed in 10% neutral formalin. They were coded on our standard histopathology request form by the progressive number.

Biopsy specimen preparation and microscopic assessment

The biopsy specimens were embedded in paraffin wax, cut into 5 μ m thick sections, and stained with hematoxylin and eosin. All biopsies were analyzed by an experienced pathologist, who was blinded about the site of biopsies at the time of histologic evaluation. The histologic adequacy of samples was assessed as that by Branski et al and by Gottrand et al.^[8,9] All histologic parameters were evaluated and histologic lesions were classified according to the Oberhuber classification^[10] with modification proposed by our group.^[11,12]

Type 0 is a normal mucosa with <25 IEL/100 epithelial cells (EC).

Type 1 is the infiltrative type, which is characterized by a normal villous architecture, a normal height of crypts, and an increase in IEL numbers >25 IEL/100 EC.

Type 2 is the hyperplastic type, which is characterized by a normal villous architecture, an increase in IEL numbers >25 IEL/100 EC, and an increase in crypt height.

Type 3 is destructive type of histologic lesion and divided into three different subgroups depending on the degree of VA.

Type 3a is characterized by a mild VA, an increase in crypt height, and an increase in IEL numbers >25 IEL/100 EC.

Type 3b is characterized by a moderate (partial) VA, an increase in crypt height, and an increase in IEL numbers >25 IEL/100 EC.

Type 3c is characterized by a severe (subtotal/total) VA, an increase in crypt height, and an increase in IEL numbers >25 IEL/100 EC.

A mucosa with a villous/crypt ratio of >3 (plus a normal IEL count) was considered as normal, whereas a decrease of the villous/crypt ratio led to the definition of atrophy as follows: 2.5-1.5 mild VA, 1-0.5 moderate (partial) VA, and <0.5 severe (subtotal/total) VA. IEL count was compared with that found in 25 children who were subjected to upper gastrointestinal endoscopy with duodenal biopsies during the study period and turned out to have problems other than CD such as gastroesophageal reflux disease ($n=12$), *Helicobacter pylori* gastritis ($n=9$), short stature ($n=2$), non-cirrhotic portal fibrosis ($n=1$), and Crohn's disease ($n=1$). IEL count was recorded as the mean of 3 representative fields from each biopsy specimen.

Statistical analysis

The categorical variables were expressed as frequencies and percentages. The continuous variables were expressed as mean \pm standard error of mean (SEM). Student's *t* test was used to compare continuous variables. Logistic regression was used to demonstrate what independent variables correlated with variability of histologic lesion in CD. A *P* value <0.05 was considered statistically significant.

Results

Demographics and clinical manifestations of CD

Sixty-seven children, 42 (62.7%) boys and 25 (37.3%) girls aged between 18 months and 17 years (mean 6.3 \pm 0.4 years), were recruited during the study period and the mean duration of their symptoms was 2.9 \pm 0.2 years (range, 6 months to 10 years). Chronic recurrent diarrhea 56/67 (83.6%), iron-deficiency anemia 51/67 (76.1%), failure to thrive 42/67 (62.7%), abdominal distension 27/67 (40.3%), and recurrent abdominal pain 15/67 (22.4%) were the main clinical manifestations of the CD patients.

Histopathologic features

Histopathologic analysis of duodenal mucosal specimens from the 67 patients indicated that VA of whatever degree was present in all CD patients irrespective of their clinical manifestations. Villous

atrophy, either subtotal/total or partial, was the predominant histologic lesions in all age groups. All CD patients had evidence of VA (type 3a, 3b, or 3c) in at least one biopsy site: type 3a in 6 (9.0%), type 3b in 12 (17.9%), and type 3c in 49 (73.1%). The classic subtotal/total VA (type 3c lesion) was seen in at least one biopsy site (Fig. 1): B₄₄ (65.7%), and D₂ 48 (71.6%). Sixteen CD patients (23.9%) showed similar degree of VA (type 3a, 3b, or 3c) in both biopsy sites, whereas 43 (64.2%) had a "mixed" type 3 lesion (Fig. 2) characterized by a different degree of VA at different biopsy sites (Figs. 2, 3). There were 59 CD patients (88.1%) with lesions of identical type (types 1, 2 or 3) in both biopsy sites. No CD patients showed exclusively type 2 or type 1 lesion in both biopsy sites. No CD patients had histologically normal biopsies at any site, and 8 CD patients (11.9%) respectively showed two different types of histologic lesions at different biopsy sites (Figs. 3, 4); the variability did not exceed 1 degree, i.e., type 1 + type 2 or type 2 + type 3. Of the 8 patients with coexistence of different types of lesion, 3 patients showed type 2 lesion in one site and type 3 lesion in the other site. In the rest 5 patients, the coexistence of different types of lesion (type 2 + type 3) was present either in one site or in both sites. The overall variability

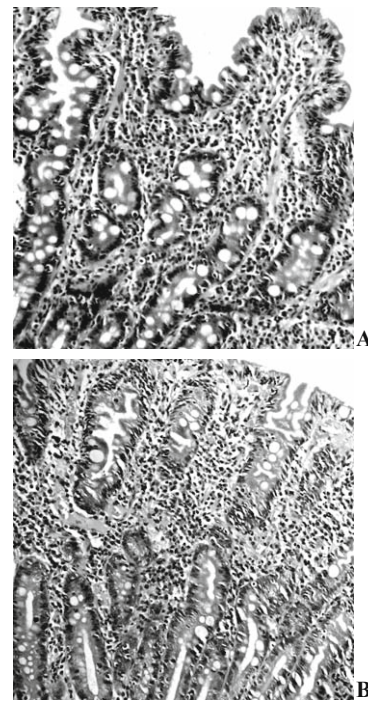


Fig. 2. Coexistent "mixed" type 3 lesion (3bc). **A:** Duodenal bulb biopsy in a patient with celiac disease revealing moderate villous atrophy (type 3b); **B:** Descending duodenum distal to papilla biopsy in the same patient showing severe villous atrophy (type 3c) lesion. (HE, original magnification × 20).

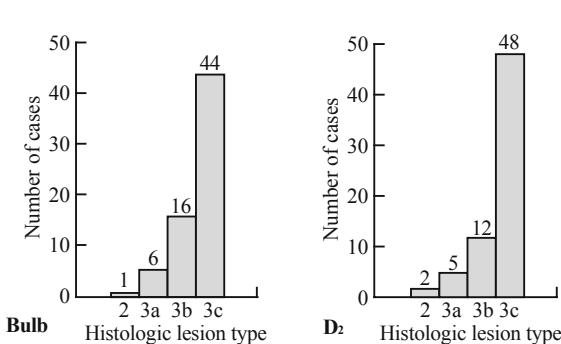


Fig. 1. Distribution of different histologic lesions in the duodenal bulb and descending duodenum (D₂) in the 67 patients with celiac disease.

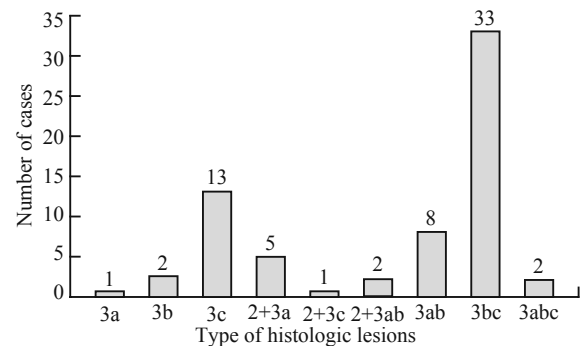


Fig. 3. Type and frequency of histologic lesions in duodenal biopsies of the 67 patients with celiac disease.

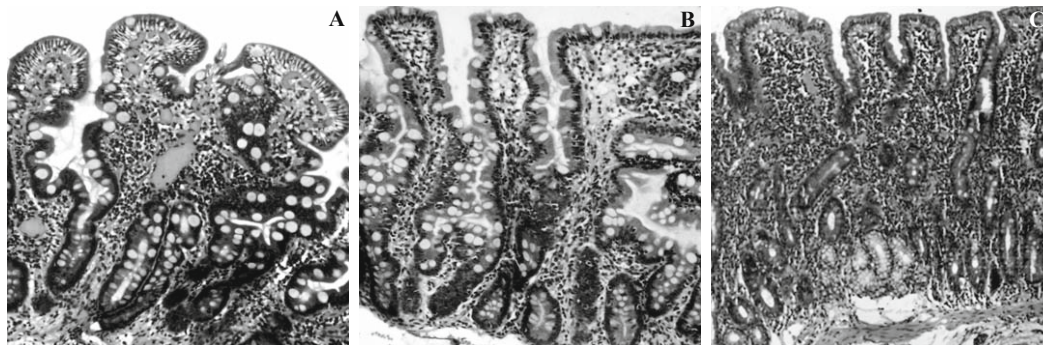


Fig. 4. Coexistent lesions of different degree (2+3ab). Duodenal bulb biopsy (**A**) in a patient with celiac disease showing hyperplastic lesion (type 2), and other area from the same biopsy site (**B**) showing mild villous atrophy lesion (type 3a). The descending duodenum distal to papilla biopsy (**C**) in the same patient showing moderate villous atrophy lesion (type 3b) (HE, original magnification × 20).

of histologic lesion (variability in the grade of VA, and coexistence of VA and type 2 lesion among different sites as well as among two different specimens from the same site) was seen in 51 (76.1%) of the CD patients. None of the 25 children (10 girls and 15 boys; mean age, 6.4±0.7 years; age range, 18 months to 14 years) with upper gastrointestinal problems other than CD had evidence of VA.

The mean duodenal IEL count in the 25 children with upper gastrointestinal problems other than CD was 18.6±0.6 (range, 12-24), whereas it was 74.3±2.6 (range, 44-132) in the CD patients ($P<0.0001$). No significant difference was observed in the IEL count between B and D₂ ($P>0.05$). All CD patients showed mild to moderate excess of chronic inflammatory cell infiltrates in the lamina propria.

The variability of histologic lesion in CD patients was not related either to age, sex, duration of symptoms, clinical manifestations such as chronic recurrent diarrhea, iron deficiency anemia, failure to thrive, abdominal distension and recurrent abdominal pain or duodenal IEL count ($P>0.05$).

Discussion

CD is an immune-mediated enteropathy triggered by the ingestion of gluten-containing grains (including wheat, rye and barley) in genetically susceptible individuals. According to the revised ESPGHAN criteria,^[1] the diagnosis of CD requires recognition of small intestinal mucosal VA with crypt hyperplasia and abnormal surface epithelium with intraepithelial lymphocytosis on a gluten-containing diet with clinical remission on a gluten-free diet. Initially the intestinal biopsy were taken by Crosby or Watson suction capsule for the diagnosis of CD,^[13] endoscopic forceps biopsies from the distal part of the duodenum later replaced jejunal biopsies, essentially because endoscopy has the major advantages of saving time and reducing the risk of failure and false negative findings.^[9,10,14,15] In fact multiple biopsies can be taken during an upper gastrointestinal endoscopy.^[10,14] At the same time various endoscopically visible changes of CD can be appreciated.

Distal duodenal biopsy is considered as a gold standard for the diagnosis of CD. The role of histopathology in diagnosing CD has been challenged.^[16] Histopathology plays a central role in diagnosis of CD. Based on the revised diagnostic criteria for CD, if the symptoms (either typical or atypical) and serological results are suggestive, a single small bowel biopsy followed by a favorable clinical and serological response to the gluten-free diet is considered sufficient to confirm

the diagnosis, provided other causes of VA including cows' milk protein intolerance and gastroenteritis are excluded.^[17] It is generally recommended that duodenal mucosal biopsy specimens should be obtained beyond the ampulla of Vater and not from the duodenal bulb. The specimens from the duodenal bulb may present problems with interpretation for an inexperienced pathologist^[14] because of the presence of gastric metaplasia, Brunner's glands and lymphoid follicle.^[5,13] In the duodenal bulb, villi can be short or blunted, or even absent in the proximity of Brunner's glands and lymphoid follicles, especially in the presence of lymphoid nodular hyperplasia, and this finding may lead to a wrong impression of VA.^[18] Histologic evaluation of mucosal biopsy specimens to rule out CD requires proper handling (oriented material), processing (cutting on edge) and interpretation. The rate of difficulty with histologic evaluation encountered because of small size or improper orientation was similar in infants and children undergoing biopsy with a Watson suction capsule or fiberoendoscope.^[19]

To detect variability of histologic lesions, multiple biopsy samples must be taken during the upper gastrointestinal endoscopy. In a few adult patients with CD, however, VA can be patchy, i.e., areas with total VA may occur in proximity to areas with mild or partial VA and possibly also areas with normal histology.^[4] In two adult patients with CD, VA was found in the duodenal bulb whereas biopsy specimens taken from the distal duodenum were entirely normal.^[5] A recent study on 102 children with CD reported that 13/95 (13.7%) newly diagnosed patients and 3/7 (42.9%) patients undergoing gluten challenge had patchy VA.^[6] In 5 of these patients, 4 newly diagnosed and one undergoing gluten challenge, total (type 3c) or moderate (type 3b) VA was present only in the duodenal bulb whereas all the four biopsy specimens taken from the distal duodenum were normal (type 0). Another study on 110 children with CD reported that the "patchiness" was due to a variability in the grade of VA in 39 patients (35.4%), to the coexistence of VA and type 2 lesion in 8 patients (7.2%), or to the coexistence of type 2 and type 1 lesion in 1 patient (0.9%).^[18] In the current study, we took at least four specimens, minimum of two biopsies each from B and D₂. We observed "patchiness" of histologic lesion in 76.1% of CD patients. The "patchiness" was due to a variability in the grade of VA in 64.2% of our patients, and 11.9% of our CD patients showed coexistence of VA and type 2 lesion, but in no cases did total or even partial VA coexist with normal histology.

The findings of the present study showed a higher frequency of variability of histologic lesion in the duodenal mucosa compared to the findings of study by Ravelli et al.^[18] There are two possible explanations

for the discrepancies between the findings of other studies^[4-6] and our findings. First, we studied only newly diagnosed CD patients and did not study those who had long been on a gluten-free diet or had recently started a gluten challenge, either prescribed by the gastroenterologist or self-administered. All of our patients were newly diagnosed and possibly duodenal damage induced by gluten occurred in the duodenal bulb in contact with gliadin fragments and the lesion extended to the descending duodenum and the proximal jejunum.^[5] But the concentration of gliadin fragments in chyme was lower in the bulb region than in the distal duodenal region. Thus, less exposure of the bulb region to toxic gliadin fragment caused less damage as compared to the distal duodenal region. In accordance with the above explanation, the present study showed more patients with type 3 lesion in D₂ as compared to bulb. Second, CD patients who undergo a gluten challenge may also be afraid of the consequences and deliberately keep their gluten intake low, thereby limiting the development of the enteropathy.^[18]

Histologic lesion variability in CD is well recognized.^[4-6,18] In addition, we explored the influence of age, sex, duration of symptoms, such clinical manifestations as chronic recurrent diarrhea, iron deficiency anemia, failure to thrive, abdominal distension and recurrent abdominal pain, and duodenal IEL count as independent variables on the histologic lesion variability in CD. It is worth noting that the influence of age, sex, duration of symptoms, various clinical manifestations and duodenal IEL count has no effect on histologic lesion variability in CD.

In conclusion, the current study revealed a high frequency of histologic lesion variability of the duodenal mucosa in Indian children with CD. This may be due to different concentrations of toxic gliadin fragment during its passage to different part of duodenal mucosa. Therefore, during upper gastrointestinal endoscopy at least 4 duodenal biopsies (2 in the distal duodenum and 2 in the duodenal bulb) should be obtained to avoid the risk of underdiagnosis or misdiagnosis because CD has a high frequency of variability of histologic lesion.

Funding: None.

Ethical approval: This study was approved by the Institute Ethic Committee of Postgraduate Institute of Medical Education and Research, Chandigarh.

Competing interest: None.

Contributors: Prasad KK designed the study, evaluated the mucosal biopsy specimens and wrote the paper. Thapa BR performed the UGI endoscopy and obtain the biopsy. Nain CK performed the serological tests. Singh K helped in designing the study and writing the paper.

References

- 1 Revised criteria for diagnosis of coeliac disease. Report of Working Group of European Society of Paediatric Gastroenterology and Nutrition. Arch Dis Child 1990;65:909-911.
- 2 Marsh MN. Gluten sensitivity and latency: can patterns of intestinal antibody secretion define the great "silent majority"? Gastroenterology 1993;104:1550-1553.
- 3 Marsh MN. Grains of truth: evolutionary changes in small intestinal mucosa in response to environmental antigen challenge. Gut 1990;31:111-114.
- 4 Scott BB, Losowsky MS. Patchiness and duodenal-jejunal variation of the mucosal abnormality in coeliac disease and dermatitis herpetiformis. Gut 1976;17:984-992.
- 5 Vogelsang H, Hänel S, Steiner B, Oberhuber G. Diagnostic duodenal bulb biopsy in celiac disease. Endoscopy 2001;33:336-340.
- 6 Bonamico M, Mariani P, Thanasi E, Ferri M, Nenna R, Tiberti C, et al. Patchy villous atrophy of the duodenum in childhood celiac disease. J Pediatr Gastroenterol Nutr 2004;38:204-207.
- 7 Lal S, Nain CK, Prasad KK, Thapa BR, Nagi B. Celiac disease in Chandigarh: a population survey. Indian J Gastroenterol 2005;24(Suppl 1):A39.
- 8 Branski D, Faber J, Freier S, Gottschalk-Sabag S, Shiner M. Histologic evaluation of endoscopic versus suction biopsies of small intestinal mucosa in children with and without celiac disease. J Pediatr Gastroenterol Nutr 1998;27:6-11.
- 9 Gottrand F, Turck D, Mitchell V, Farriaux JP. Comparison of fiberendoscopy and Watson capsule for small intestinal biopsy in infants and children. Acta Paediatr 1992;81:399-401.
- 10 Oberhuber G, Granditsch G, Vogelsang H. The histopathology of coeliac disease: time for a standardized report scheme for pathologists. Eur J Gastroenterol Hepatol 1999;11:1185-1194.
- 11 Prasad KK, Thapa BR, Nain CK, Singh K. Assessment of the diagnostic value of duodenal bulb histology in patients with celiac disease, using multiple biopsy sites. J Clin Gastroenterol 2009;43:307-311.
- 12 Prasad KK, Thapa BR, Nain CK, Sharma AK, Singh K. Brush border enzyme activities in relation to histological lesion in pediatric celiac disease. J Gastroenterol Hepatol 2008;23(8 Pt 2):e348-352.
- 13 Trier JS. Diagnostic value of peroral biopsy of the proximal small intestine. N Engl J Med 1971;285:1470-1473.
- 14 Achkar E, Carey WD, Petras R, Sivak MV, Revta R. Comparison of suction capsule and endoscopic biopsy of small bowel mucosa. Gastrointest Endosc 1986;32:278-281.
- 15 Granot E, Goodman-Weill M, Pizov G, Sherman Y. Histological comparison of suction capsule and endoscopic small intestinal mucosal biopsies in children. J Pediatr Gastroenterol Nutr 1993;16:397-401.
- 16 Drut R, Rúa EC. The histopathology of pediatric celiac disease: order must prevail out of chaos. Int J Surg Pathol 2001;9:261-264.
- 17 Farrell RJ, Kelly CP. Diagnosis of celiac sprue. Am J Gastroenterol 2001;96:3237-3246.
- 18 Ravelli A, Bolognini S, Gambarotti M, Villanacci V. Variability of histologic lesions in relation to biopsy site in gluten-sensitive enteropathy. Am J Gastroenterol 2005;100:177-185.
- 19 Gottrand F, Michaud L. Comparison of fiberendoscopy and suction capsule for small intestinal biopsy in children with and without celiac disease. J Pediatr Gastroenterol Nutr 1999;28:353-356.

Received August 18, 2008

Accepted after revision December 29, 2008