

# Changing pattern of indications of endoscopic retrograde cholangiopancreatography in children and adolescents: a twelve-year experience

Carlos O Kieling, Cristiane Hallal, Camila O Spessato, Luciana M Ribeiro, Helenice Breyer, Helena AS Goldani, Ismael Maguilnik

Porto Alegre-RS, Brazil

**Background:** There are few data regarding endoscopic retrograde cholangiopancreatography (ERCP) usefulness in children and adolescents. We reviewed the long-term experience with diagnostic and therapeutic ERCP in a tertiary single center in Southern Brazil.

**Methods:** A retrospective chart review of patients aged 0-18 years who had undergone ERCs from January 2000 to June 2012 was done. Data on demographics, indications, diagnosis, treatments, and complications were collected.

**Results:** Seventy-five ERCs were performed in 60 patients. The median age of the patients at the procedure was 13.9 years (range: 1.2-17.9). Of the 60 patients, 47 (78.3%) were girls. Of all ERCs, 48 (64.0%) were performed in patients above 10 years and 35 (72.9%) of them were in girls. ERCP was indicated for patients with bile duct obstruction (49.3%), sclerosing cholangitis (18.7%), post-surgery complication (12%), biliary stent (10.7%), choledochal cyst (5.3%), and pancreatitis (4%). The complication rate of ERCP was 9.7% involving mild bleeding, pancreatitis and cholangitis. Patients who had therapeutic procedures were older ( $13.7 \pm 3.9$  vs.  $9.9 \pm 4.9$  years;  $P=0.001$ ) and had more extrahepatic biliary abnormalities (82% vs. 50%;  $P=0.015$ ) than

those who had diagnostic ERCs. A marked change in the indications of ERCs was found, i.e., from 2001 to 2004, indications were more diagnostic and from 2005 therapeutic procedures were predominant.

**Conclusions:** Diagnostic ERCs are being replaced by magnetic resonance cholangiopancreatography and also by endoscopic ultrasound. All these procedures are complementary and ERCP still has a role for therapeutic purposes.

*World J Pediatr* 2015;11(2):154-159

**Key words:** adolescents;  
cholangiopancreatography;  
endoscopic retrograde

## Introduction

Endoscopic retrograde cholangiopancreatography (ERCP) is a recognized tool for the diagnosis and management of pancreatobiliary diseases.<sup>[1]</sup> ERCP guidelines have been well established in adults<sup>[2]</sup> but not for the pediatric population since its use is limited due to the low prevalence of pancreatobiliary diseases in this age group, technical and equipment limitations despite the advent of new duodenoscopes appropriate for the pediatric age, and the paucity of data regarding formal indications and safety.<sup>[3,4]</sup> The prevalence of different types of biliary and pancreatic diseases varies worldwide and, as a consequence, indications of ERCP may change in particular geographic areas.<sup>[5]</sup> Data regarding the utility and safety of ERCP in the pediatric population are limited to small sample sizes of patients.<sup>[6,7]</sup>

Given the lack of evidence-based guidelines for the use of ERCs in children, this study aimed to review the 12-year experience with ERCs in a single referral center in Southern Brazil in order to assess its usefulness and safety.

**Author Affiliations:** Post-Graduate Program of Sciences in Gastroenterology and Hepatology, Universidade Federal do Rio Grande do Sul (Kieling CO, Hallal C, Goldani HAS); Pediatric Gastroenterology Unit, Hospital de Clínicas de Porto Alegre, Faculdade de Medicina, Universidade Federal do Rio Grande do Sul, Brazil (Kieling CO, Hallal C, Spessato CO, Ribeiro LM, Goldani HAS); Endoscopy Service, Hospital de Clínicas de Porto Alegre, Faculdade de Medicina, Universidade Federal do Rio Grande do Sul, Brazil (Breyer H, Maguilnik I)

**Corresponding Author:** Cristiane Hallal, Rua Ramiro Barcelos 2350, Porto Alegre-RS 90035-903, Brazil (Tel: 55-51-33597859; Fax: 55-51-33597859; Email: cris.hallal@yahoo.com)

doi:10.1007/s12519-014-0518-5

©Children's Hospital, Zhejiang University School of Medicine, China and Springer-Verlag Berlin Heidelberg 2014. All rights reserved.

## Methods

### Study design

This study was approved by the Research Ethics Committee of Hospital de Clínicas de Porto Alegre. From January 2000 to June 2012, the medical charts and ERCP reports of all patients under 18 years who had undergone ERCP were retrospectively reviewed from a specific hospital database and there were no missing data regarding patients who underwent ERCP. Data were collected regarding demographics, indications for the procedure, preoperative and final diagnosis, anesthesia type, success rate, treatment performed, and complications.

Indications were defined as therapeutic when a pancreaticobiliary disease treatable by ERCP was suspected based on clinical symptoms. Such treatments might be biliary sphincterotomy, bile duct stone extraction, biliary stricture dilation, biliary endoprosthesis, nasobiliary drainage tube placement, and bile duct orifice dilation. Diagnostic indication of ERCP was defined as the procedure when a pancreaticobiliary disease was suspected with no probable further therapeutic intervention.

All ERCP procedures were performed at Endoscopic Unit, Hospital de Clínicas de Porto Alegre, a tertiary referral center for adult and pediatric gastroenterology and endoscopy. All procedures were performed by two well-trained endoscopists (BH and MI).

Procedures were performed in the Radiology Service and additional procedures such as stone extraction or stent placement were performed under radiological guidance. The ionic contrast Telebrix® 30 Meglumina (Guerbet Ltda, Rio de Janeiro, RJ) was used to opacify the pancreaticobiliary ducts. Obliteration of the intrahepatic biliary duct was defined by the absence of opacification of peripheral intrahepatic branches after injection of contrast under pressure.

Employed endoscope was the "diagnostic" duodenoscope (JF-100 Olympus America Corp., Melville, N.Y.), which has an outer diameter of 11.5 mm and an accessory channel diameter of 3.2 mm with a "therapeutic" duodenoscope (TJF-140; Olympus), with an outer diameter of 12.5 mm and accessory channel diameter of 4.2 mm.

Type of anesthesia was based on patient's age, anticipated patient collaboration, and pre-procedure diagnosis. Medications used were propofol alone or combined with midazolam and/or fentanyl and general anesthesia. All patients were assisted by an anesthesiologist following the American Society of Anesthesiologists classification as the hospital standard guidelines. All patients had cardiorespiratory monitoring by pulse oximeter and electrocardiogram

assessment. No prophylactic antibiotics were used as it was not a local routine procedure.

### Definition of complications

Following ERCP, the clinical status of children and liver and pancreatic function tests were monitored during the week after the procedure. Oral diet was initiated on the same day if the child did not complain of abdominal pain and if there was no significant increase in pancreatic enzymes 6 hours after the procedure. Success of the procedure was defined by the cannulation of the ampulla with biliary duct and/or pancreatic duct imaging. Failure of the procedure was defined as failure of cannulation after 6 attempts.

Pancreatitis was defined as the occurrence of abdominal pain associated with serum levels of amylase and lipase three times higher than normal values according to the age 24 hours or more after ERCP. Other ERCP-related complications were defined and graded in severity according to the consensus criteria developed by Cotton et al.<sup>[8,9]</sup>

### Statistical analysis

Data were presented as mean±SD. Statistical analysis was performed by using the chi-square test, Fisher's Exact test, and Student's *t* test. Significance level was considered when  $P < 0.05$ . Statistical analysis was performed using SPSS software version 18.

## Results

Over the 12-year study period, 75 ERCPs were performed in 60 patients from 1 to 18 years of age at our institution. The median age of the patients at the procedure was 13.9 years (range: 1.2-17.9). In this series, 47 ERCPs (62.7%) were performed in girls and 48 ERCPs (64.0%) in patients above 10 years. In patients aged 1 to 10 years, gender was equally distributed, but in those above 10 years ERCPs were

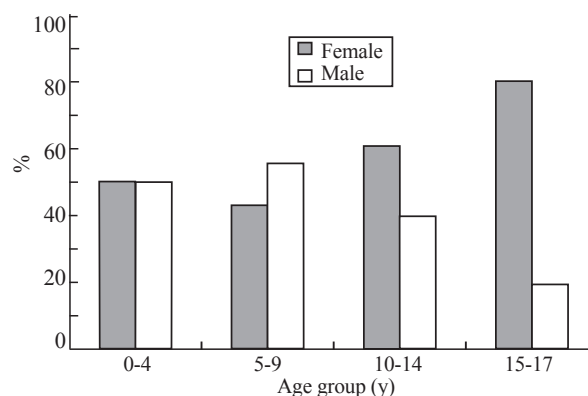


Fig. 1. Age and gender distribution.

**Table 1.** Indications for endoscopic retrograde cholangiopancreatography

Variables	Diagnostic, n (%)	Therapeutic, n (%)	Total, n (%)
Biliary obstruction	2 (8.3)	35 (68.6)	37 (49.3)
Investigation of biliary cirrhosis/sclerosing cholangitis	14 (58.3)	0 (0.0)	14 (18.7)
Complication of biliary surgery/liver transplant	2 (8.3)	7 (13.7)	9 (12.0)
Removal or replacement of biliary stent	0 (0.0)	8 (15.7)	8 (10.7)
Choledochal cyst	4 (16.7)	0 (0.0)	4 (5.3)
Acute and recurrent pancreatitis	2 (8.3)	1 (2.0)	3 (4.0)
Total	24 (32.0)	51 (68.0)	75 (100.0)

performed more frequently in girls (72.9%) than in boys (Fig. 1).

The indications of ERCPs are shown in Table 1. ERCPs were indicated diagnostically for 32% of the patients but therapeutically for 68%. Two patients underwent ERCP because of acute pancreatitis suggested by the presence of *Ascaris lumbricoides* in the pancreaticobiliary duct shown by abdominal ultrasound.

Fifty-one patients had a single procedure, whereas 9 patients underwent more than one intervention (5 patients had 2 ERCPs, 2 had 3 ERCPs, and 2 had 4 ERCPs). The patients who underwent several ERCPs had post-surgery biliary complications such as post-liver transplantation biliary stenosis and post-cholecystectomy leak. The mean number of procedures per year was 6 (range: 4-13).

With regard to the type of sedation, 30 (40%) procedures were performed under general anesthesia and 45 (60%) under sedation and topical anesthesia of the pharynx with xylocaine spray. Variable doses of intravenous fentanyl and/or midazolam for conscious

sedation and propofol for deep sedation were used.

The ampulla was cannulated and the procedure was successfully completed in 71 (94.7%) procedures. Four failures of cannulation were seen in 3 patients (2 patients had one failure each and another patient had 2 failures after 2 ERCP procedures).

ERCs results are shown in Table 2. Fifty-five therapeutic procedures were performed (papilla sphincterotomy in 31 patients, stone extraction in 13, removal/replacement of biliary stent in 10, and removal of *Ascaris lumbricoides* in 1).

Five patients had mild acute pancreatitis, 1 had mild cholangitis and 1 had mild papilla bleeding. The overall complication rate was 9.3% (7/75). All of the patients were treated conservatively in less than 7 days with antibiotics and adrenalin, respectively. There was no mortality. Increased serum amylase and lipase after ERCPs were seen in 32 patients. Of these patients, 19 (59.4%) had increased rates 3 times higher than normal values, but all patients were asymptomatic. No pancreatic duct stents were placed for prophylaxis of post-ERCP pancreatitis.

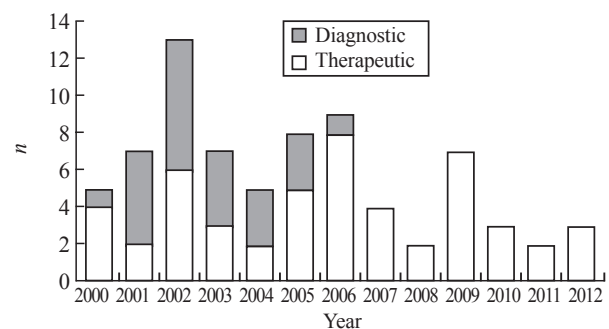
Most of the patients aged above 10 years were girls (72.9% vs. 27.1%,  $P=0.024$ ). Similarly, girls had diagnostic procedures rather than therapeutic ones (83.3% vs. 16.7%,  $P=0.012$ ). With regard to abnormalities found on ERCP, there was no significant difference between boys and girls ( $P>0.05$ ).

The patients who had therapeutic procedures were older ( $13.7\pm 3.9$  vs.  $9.9\pm 4.9$  years,  $P=0.001$ ) and had more extrahepatic biliary abnormalities (82% vs. 50%,

**Table 2.** Findings of 75 endoscopic retrograde cholangiopancreatography

Variables	n (%)
Extrahepatic biliary abnormality	51 (68.0)
Obstructive biliary flow	26 (34.7)
Choledocholithiasis	14 (18.7)
<i>Ascaris lumbricoides</i>	1 (1.3)
Post-surgical stenosis*	11 (14.7)
Extrahepatic biliary stenosis	13 (17.3)
Sclerosing cholangitis	2 (2.7)
Post-surgical stenosis	11 (14.7)
Dilation of extrahepatic bile duct	17 (22.7)
Gallstone	21 (28.0)
Gallbladder	7 (9.3)
Choledochal	12 (16.0)
Papillary	2 (2.7)
Extrahepatic biliary cyst	3 (4.0)
Biliary fistula	3 (4.0)
Intrahepatic biliary abnormality	17 (22.7)
Dilation of intrahepatic biliary duct	12 (16.0)
Obliteration of intrahepatic biliary duct	13 (17.3)
Pancreas divisum	2 (2.7)
Normal	12 (16.0)
Failure of procedure	4 (5.3)

\*: post-hepatectomy and post-liver transplantation.

**Fig. 2.** Diagnostic and therapeutic indications of endoscopic retrograde cholangiopancreatography in the period of 2000-2012.

$P=0.015$ ) than those who had diagnostic ERCPs. Intrahepatic abnormalities were observed more frequently in diagnostic ERCPs than in therapeutic ones (45% vs. 16.7%,  $P=0.026$ ).

There was a marked change in indications for ERCPs over the period of 2000-2012. In the first years, from 2001 to 2004, indications were more diagnostic, whereas from 2005 onwards therapeutic procedures were predominant, and since 2007 no more diagnostic indications were followed in our service (Fig. 2).

## Discussion

This study described a single center experience with ERCPs in a population aged from 1 to 18 years. This study highlighted the changes in indications for ERCP in the new era following the advent of imaging techniques, such as magnetic resonance cholangiopancreatography (MRCP) and endoscopic ultrasound (EUS).<sup>[10-12]</sup>

This is the first study in this age group from Southern Brazil. The indications for ERCP in our patients (choledocholithiasis and acute pancreatitis) were according to those described for Western adults<sup>[2]</sup> and children.<sup>[13,14]</sup> On the other hand, different indications were seen in Asian and Mediterranean countries that have a high prevalence of sickle cell disease and thus a high incidence of cholelithiasis and choledocholithiasis.<sup>[15-17]</sup> Choledochal cyst was the most frequent indication in Japan, India and Korea.<sup>[3,6,18]</sup> Recently, a large Western series has shown chronic or recurrent pancreatitis as the most common indication for ERCP and gallstone disease was an indication for only 26% of all ERCPs.<sup>[19]</sup> This might reflect the finding that gallstones in prepubertal children are rare as the patients of that study were younger than ours.

Differently from other studies in similar age groups, the second commonest indication for ERCP in our study was the investigation of biliary cirrhosis/sclerosing cholangitis. This might be due to the local characteristics of the Pediatric Unit as it is a referral center for liver diseases and liver transplantation; even though these indications have a decreasing trend as ERCPs are currently being gradually replaced by MRCPs in this group of patients.<sup>[20,21]</sup> Some studies have described more non-liver disease-related indications for ERCP such as chronic or acute pancreatitis, choledochal cyst and choledocholithiasis.<sup>[6,7,19,22,23]</sup> Another study has shown 84% of biliary indications and the majority of patients were younger than 1 year.<sup>[24]</sup>

In this study, the majority of patients above 10 years were girls and they had more diagnostic than therapeutic procedures. With regard to abnormalities

found on ERCP, there was no significant difference between boys and girls, apart from gallstone disease which was higher in girls. These findings may be a reflex of the high risk of gallstone disease in females, especially from the fertile years onwards as this may be related to the female sex hormones.<sup>[25]</sup>

In this study, ERCP was successfully performed in 94.7% of the patients, which is in accordance with that in a similar age group ranging from 89.5% to 97.5%.<sup>[6,12,22,26-28]</sup> Some factors may impair the success of the cannulation of the ampulla with biliary duct and/or pancreatic duct imaging such as anatomical abnormalities, previous surgery and inadequate sedation.<sup>[29,30]</sup> Nonetheless, successful cannulation rates at or above 95% are consistently achieved by experienced endoscopists.<sup>[30,31]</sup>

The complication rate after ERCP was reported to range from 3.4% to 28.5% in children and pancreatitis was the most common cause.<sup>[6,14,22,24-27,32,33]</sup> In our study, the complication rate was 10% and acute pancreatitis was the most common minor complication, which is similar to the rate in adults (10%).<sup>[34-36]</sup> This finding indicates the skills and experience of the endoscopists. The complication rate is lower in adult ERCPs performed by endoscopists who perform 100 ERCPs than by those who perform 40 ERCPs per year.<sup>[37]</sup> We believe that the pancreatitis rate post-ERCP in our study would have been lower if some prophylactic strategies had been employed. In adults, pancreatic stent has been recommended for patients at high risk and periprocedural rectal administration of nonsteroidal anti-inflammatory drugs for low-risk patients with post-ERCP pancreatitis.<sup>[38,39]</sup> However, these prophylactic strategies were not used in our series.

In the past decades, new diagnostic modalities for pancreatobiliary disorders have been developed, including MRCP and EUS in adults and children.<sup>[11,12]</sup> MRCP seems to be an alternative to ERCP in the assessment of various entities such as choledochal cyst, recurrent pancreatitis, primary sclerosing cholangitis, and post-liver transplantation biliary stenosis.<sup>[7,40-45]</sup> As in other centers,<sup>[32]</sup> ERCPs in our service are being replaced by MRCPs for diagnostic purpose since 2004 following the development of MRCPs. Nevertheless, ERCP is still considered important as a therapeutic procedure for gallstone diseases.<sup>[1]</sup> In our study, therapeutic procedures accounted for 73.3% of all ERCPs, of which 67.3% were indicated for biliary obstruction.

There were several limitations in this study. This study was a retrospective review, and many data regarding long-term follow up to assess later complications of the procedures were missed. However, we found that patients who underwent therapeutic ERCPs were older and had more extrahepatic biliary

abnormalities than those who had diagnostic ERCPs. The patients who had diagnostic ERCPs had intra-hepatic abnormalities.

In conclusion, ERCP is a useful and safe procedure for children and adolescents with a complication rate similar to that seen in adults. Diagnostic ERCPs are being replaced by MRCPs and EUSs, but ERCPs are still used for therapeutic purposes.

**Funding:** This study was funded by FIPE - Hospital de Clinicas de Porto Alegre.

**Ethical approval:** This study was approved by the Research Ethics Committee of Hospital de Clinicas de Porto Alegre.

**Competing interest:** All authors declare no conflict of interest.

**Contributors:** KCO was responsible for the research design and data analysis. HC, SCO and RLM collected the data. GHAS analyzed the data and wrote the manuscript. BH and MI performed the ERCP procedures. All authors read and approved the final version of the manuscript.

## References

- Williams CI, Shaffer EA. Gallstone disease: current therapeutic practice. *Curr Treat Options Gastroenterol* 2008;11:71-77.
- Adler DG, Baron TH, Davila RE, Egan J, Hirota WK, Leighton JA, et al. Standards of Practice Committee of American Society for Gastrointestinal Endoscopy. ASGE guideline: the role of ERCP in diseases of the biliary tract and the pancreas. *Gastrointest Endosc* 2005;62:1-8.
- Poddar U, Thapa BR, Bhasin DK, Prasad A, Nagi B, Singh K. Endoscopic retrograde cholangiopancreatography in the management of pancreaticobiliary disorders in children. *J Gastroenterol Hepatol* 2001;6:927-931.
- Issa H, Al-Haddad A, Al-Salem AH. Diagnostic and therapeutic ERCP in the pediatric age group. *Pediatr Surg Int* 2007;23:111-116.
- Javid G, Zargar S, Shah A, Shoukat A, Iqbal A, Gupta A. Etiology and outcome of acute pancreatitis in children in Kashmir (India). An endemic area of hepatobiliary ascariasis. *World J Surg* 2013;37:1133-1140.
- Jang JY, Yoon CH, Kim KM. Endoscopic retrograde cholangiopancreatography in pancreatic and biliary tract disease in Korean children. *World J Gastroenterol* 2010;16:490-495.
- De Angelis P, Foschia F, Romeo E, Caldaro T, Rea F, di Abriola GF, et al. Role of endoscopic retrograde cholangiopancreatography in diagnosis and management of congenital choledochal cysts: 28 pediatric cases. *J Pediatr Surg* 2012;47:885-888.
- Williams EJ, Taylor S, Fairclough P, Hamlyn A, Logan RF, Martin D, et al. Risk factors for complication following ERCP; results of a large-scale, prospective multicenter study. *Endoscopy* 2007;39:793-801.
- Cotton PB, Lehman G, Vennes J, Geenen JE, Russell RC, Meyers WC, et al. Endoscopic sphincterotomy complications and their management an attempt at consensus. *Gastrointest Endosc* 1991;37:383-393.
- Pannu DS, Draganov PV. Therapeutic endoscopic retrograde cholangiopancreatography and instrumentation. *Gastrointest Endosc Clin N Am* 2012;22:401-416.
- NIH state-of-the-science statement on endoscopic retrograde cholangiopancreatography (ERCP) for diagnosis and therapy. *NIH Consens State Sci Statements* 2002;19:1-26.
- Al-Rashdan A, LeBlanc J, Sherman S, McHenry L, DeWitt J, Al-Haddad M. Role of endoscopic ultrasound for evaluating gastrointestinal tract disorders in pediatrics: a tertiary care center experience. *J Pediatr Gastroenterol Nutr* 2010;51:718-722.
- Pfau PR, Chelimsky GG, Kinnard MF, Sivak MV Jr, Wong RC, Isenberg GA, et al. Endoscopic retrograde cholangiopancreatography in children and adolescents. *J Pediatr Gastroenterol Nutr* 2002;35:619-623.
- Cheng CL, Fogel EL, Sherman S, McHenry L, Watkins JL, Croffie JM, et al. Diagnostic and therapeutic endoscopic retrograde cholangiopancreatography in children: a large series report. *J Pediatr Gastroenterol Nutr* 2005;41:445-453.
- Curro G, Meo A, Ippolito D, Pusiol A, Cucinotta E. Asymptomatic cholelithiasis in children with sickle cell disease: early or delayed cholecystectomy? *Ann Surg* 2007;245:126-129.
- Al-Salem AH, Issa H. Laparoscopic cholecystectomy in children with sickle cell anemia and the role of ERCP. *Surg Laparosc Endosc Percutan Tech* 2012;22:139-142.
- Issa H, Al-Haddad A, Al-Salem A. Sickle cell cholangiopathy: an endoscopic retrograde cholangiopancreatography evaluation. *World J Gastroenterol* 2009;15:5316-5320.
- Teng R, Yokohata K, Utsunomiya N, Takahata S, Nabae T, Tanaka M. Endoscopic retrograde cholangiopancreatography in infants and children. *J Gastroenterol* 2000;35:39-42.
- Otto AK, Neal MD, Slivka AN, Kane TD. An appraisal of endoscopic retrograde cholangiopancreatography (ERCP) for pancreaticobiliary disease in children: our institutional experience in 231 cases. *Surg Endosc* 2011;25:2536-2540.
- Meagher S, Yusoff I, Kennedy W, Martel M, Adam V, Barkun A. The roles of magnetic resonance and endoscopic retrograde cholangiopancreatography (MRCP and ERCP) in the diagnosis of patients with suspected sclerosing cholangitis: a cost-effectiveness analysis. *Endoscopy* 2007;39:222-228.
- Linhares MM, Coelho RD, Szejnfeld J, Goldman SM, Gonzalez AM, Szejnfeld D, et al. Evaluation of the efficacy and reproducibility of cholangiopancreatography by magnetic resonance for detecting biliary complications following orthotopic liver transplantation. *Acta Cir Bras* 2010;25:249-256.
- Paris C, Bejjani J, Beaunoyer M, Ouimet A. Endoscopic retrograde cholangiopancreatography is useful and safe in children. *J Pediatr Surg* 2010;45:938-942.
- Taj MA, Leghari A, Qureshi S, Ghazanfar S, Niaz SK, Quraishy MS. Endoscopic retrograde cholangiopancreatography: a therapeutic modality in children and adolescents. *J Pak Med Assoc* 2012;62:98-101.
- Vegting IL, Tabbers MM, Taminiau JA, Aronson DC, Benninga MA, Rauws EA. Is endoscopic retrograde cholangiopancreatography valuable and safe in children of all ages? *J Pediatr Gastroenterol Nutr* 2009;48:66-71.
- Stinton LM, Myers RP, Shaffer EA. Epidemiology of gallstones. *Gastroenterol Clin North Am* 2010;39:157-169.
- Prasil P, Laberge JM, Barkun A, Flageole H. Endoscopic retrograde cholangiopancreatography in children: a surgeon's perspective. *J Pediatr Surg* 2001;36:733-735.
- Varadarajulu S, Wilcox CM, Hawes RH, Cotton PB. Technical outcomes and complications of ERCP in children. *Gastrointest Endosc* 2004;60:367-371.
- Green JA, Scheeres DE, Conrad HA, Cloney DL, Schlatter

- MG. Pediatric ERCP in a multidisciplinary community setting: experience with a fellowshiptrained general surgeon. *Surg Endosc* 2007;21:187-192.
- 29 Jowell PS, Baillie J, Branch MS, Affronti J, Browning CL, Bute BP. Quantitative assessment of procedural competence. A prospective study of training in endoscopic retrograde cholangiopancreatography. *Ann Intern Med* 1996;125:983-989.
- 30 Baron TH, Petersen BT, Mergener K, Chak A, Cohen J, Deal SE, et al. Quality indicators for endoscopic retrograde cholangiopancreatography. *Am J Gastroenterol* 2006;101:892-897.
- 31 Schlup MM, Williams SM, Barbezat GO. ERCP: a review of technical competency and workload in a small unit. *Gastrointest Endosc* 1997;46:48-52.
- 32 Rocca R, Castellino F, Daperno M, Masoero G, Sostegni R, Ercole E, et al. Therapeutic ERCP in paediatric patients. *Dig Liver Dis* 2005;37:357-362.
- 33 Iqbal CW, Baron TH, Moir CR, Ishitani MB. Post-ERCP pancreatitis in pediatric patients. *J Pediatr Gastroenterol Nutr* 2009;49:430-434.
- 34 Andriulli A, Loperfido S, Napolitano G, Niro G, Valvano MR, Spirito F, et al. Incidence rates of post-ERCP complications: a systematic survey of prospective studies. *Am J Gastroenterol* 2007;102:1781-1788.
- 35 Wang P, Li ZS, Liu F, Ren X, Lu NH, Fan ZN, et al. Risk factors for ERCP-related complications: a prospective multicenter study. *Am J Gastroenterol* 2009;104:31-40.
- 36 Testoni PA, Vailati C, Giussani A, Notaristefano C, Mariani A. ERCP-induced and non-ERCP-induced acute pancreatitis: Two distinct clinical entities with different outcomes in mild and severe form? *Dig Liver Dis* 2010;42:567-570.
- 37 Rabenstein T, Schneider HT, Nicklas M, Ruppert T, Katalinic A, Hahn EG, et al. Impact of skill and experience of the endoscopist on the outcome of endoscopic sphincterotomy techniques. *Gastrointest Endosc* 1999;50:628-636.
- 38 Moon SH, Kim MH. Prophecy about post-endoscopic retrograde cholangiopancreatography pancreatitis From divination to science. *World J Gastroenterol* 2013;19:631-637.
- 39 Dumonceau JM, Andriulli A, Deviere J, Mariani A, Rigaux J, Baron TH, et al. European Society of Gastrointestinal Endoscopy (ESGE) Guideline: prophylaxis of post-ERCP pancreatitis. *Endoscopy* 2010;42:503-515.
- 40 Tipnis NA, Werlin SL. The use of magnetic resonance cholangiopancreatography in children. *Curr Gastroenterol Rep* 2007;9:225-229.
- 41 Fitoz S, Erden A, Boruban S. Magnetic resonance cholangiopancreatography of biliary system abnormalities in children. *Clin Imaging* 2007;31:93-101.
- 42 Huang CT, Lee HC, Chen WT, Jiang CB, Shih SL, Yeung CY. Usefulness of magnetic resonance cholangiopancreatography in pancreatobiliary abnormalities in pediatric patients. *Pediatr Neonatol* 2011;52:332-336.
- 43 Dong Q, Jiang BX, Jiang Z, Zhang H, Zhao N, Jiang XM, et al. Management of congenital choledochal cyst complicated by biliary anomalies and aberrant bile duct. *World J Pediatr* 2006;2:133-138.
- 44 Chavhan GB, Babyn PS, Manson D, Vidarsson L. Pediatric MR cholangiopancreatography: principles, technique, and clinical applications. *Radiographics* 2008;28:1951-1962.
- 45 Jorgensen JE, Waljee AK, Volk ML, Sonnenday CJ, Elta GH, Al-Hawary MM, et al. Is MRCP equivalent to ERCP for diagnosing biliary obstruction in orthotopic liver transplant recipients? A meta-analysis. *Gastrointest Endosc* 2011;73:955-962.

Received February 21, 2014

Accepted after revision July 22, 2014