

# Neonatal necrotizing enterocolitis: clinical aspects, experimental models and pathogenesis

Wei Hsueh, Isabelle G. De Plaen, Michael S. Caplan, Xiao-Wu Qu, Xiao-Di Tan, F. Gonzalez-Crussi

Chicago and Evanston, USA

**Background:** Necrotizing enterocolitis (NEC), a disease of premature infants, is a leading cause of morbidity and mortality in neonatal intensive care units. Its known predisposing factors include prematurity, enteral feeding, and infection, but the pathogenesis is still obscure.

**Data sources and Results:** Several animal models of NEC have been established in adult and neonatal rats and mice. Endogenous mediators, especially platelet-activating factor (PAF), play a pivotal role in NEC. Injection of PAF results in intestinal necrosis, and PAF antagonists prevent the bowel injury induced by endotoxin, hypoxia, or tumor necrosis factor- $\alpha$  (TNF) in adult rats. PAF antagonists or PAF-acetylhydrolase, the enzyme degrading PAF, also ameliorate the pathology of the neonatal model induced by hypoxia and enteral feeding. Human patients with NEC have elevated levels of plasma PAF and decreased PAF-acetylhydrolase. However, to exert its injurious action, PAF requires the presence of commensal bacteria in the intestine. The initial event in our models of NEC is probably polymorphonuclear leukocytes (PMN) activation and adhesion to venules in the intestine, probably in response to local PAF release. Other molecules and mediators taking part in the process include NF- $\kappa$ B, TNF, chemokines (especially MIP-2/CXCL2), and the complement system, leading to a local inflammatory reaction. Subsequent release of vasoconstrictors and the consequent mesenteric vasoconstriction result in splanchnic ischemia and reperfusion. Toxins from commensal bacteria (e.g., endotoxin) enter the intestinal

tissue during local mucosal barrier breakdown, and synergize with PAF and TNF to amplify the inflammation. Reactive oxygen species produced by the activated leukocytes and by intestinal epithelial xanthine oxidase may be the final effector for tissue injury. Protective mechanisms include nitric oxide produced by the constitutive (mainly neuronal) nitric oxide synthase (which maintains intestinal perfusion and the integrity of the mucosal barrier), and the innate immune response, enhanced by indigenous probiotics such as Bifidobacteria and Lactobacilli.

**Conclusions:** The eventual development of severe bowel necrosis depends on the balance between the injurious and the protective mechanisms. The injurious includes various pro-inflammatory molecules such as PAF, leukotrienes, TNF, chemokines, the complement system, vasoconstrictors, adhesion molecules, xanthine oxidase, reactive oxygen species, NF- $\kappa$ B and products of commensal bacteria such as lipopolysaccharide. The protective mechanisms include neuronal nitric oxide synthase, PAF acetylhydrolase, and probiotics.

*World J Pediatr 2007;3(1):17-29*

**Key words:** necrotizing enterocolitis; platelet-activating factor; tumor necrosis factor; nuclear factor kappa B; chemokines; reactive oxygen species; nitric oxide synthesis; probiotics; intestines

## List of abbreviations:

eNOS: endothelial NOS. ICAM-1: intercellular adhesion molecule-1. iNOS: inducible NOS. LPS: lipopolysaccharide (bacterial endotoxin). LTC<sub>4</sub>: leukotriene C<sub>4</sub>. MPO: myeloperoxidase. NEC: necrotizing enterocolitis. NF- $\kappa$ B: nuclear factor-kappa B. nNOS: neuronal NOS. NO: nitric oxide. NOS: nitric oxide synthase. PAF: platelet-activating factor. PAF-AH: PAF acetylhydrolase. PAF-R: PAF receptor. PLA<sub>2</sub>: phospholipase A<sub>2</sub>. PMN: polymorphonuclear leukocytes. ROS: reactive oxygen species. TNF: tumor necrosis factor- $\alpha$ . XD: xanthine dehydrogenase. XO: xanthine oxidase. VLBW: very low birth weight.

**Author Affiliations:** Department of Pathology, Northwestern University Medical School, Chicago, IL 60614, USA (Hsueh W, Tan XD, Gonzalez-Crussi F, Qu XW); Department of Pediatrics, Children's Memorial Hospital, Northwestern University Medical School, Chicago, IL 60614, USA (De Plaen IG); Department of Pediatrics, Evanston Hospital, Northwestern University Medical School, Evanston, IL 60201, USA (Caplan MS)

**Corresponding Author:** Wei Hsueh, MD, PhD, Department of Pathology, Children's Memorial Hospital, Chicago, IL 60614, USA (Tel: 1-773-880-4364; Fax: 1-773-880-8127; Email: w-hsueh@northwestern.edu)

©2007, World J Pediatr. All rights reserved.

## Clinical considerations

Necrotizing enterocolitis (NEC) remains a leading cause of mortality in the neonatal intensive care unit. Amongst survivors, many suffer from long-term complications such as short bowel syndrome and its consequences. The incidence of NEC varies between 0.3 and 2.4 infants per 1000 births and between 4% and 22% amongst infants with birth weight less than 1500 g. The disease involves mostly premature infants. The age at onset is inversely related to gestational age (mean age at onset of 3 weeks for <30 weeks, 2 weeks for 31-33 weeks, 5 days for >34 weeks and 2 days for full-term infants).<sup>[1-4]</sup> NEC is uncommon in term infants; only 10% of the affected infants are full term. Presumably, a postnatal insult is followed by the pathogenetic events that lead to the tissue devastation characteristic of NEC.

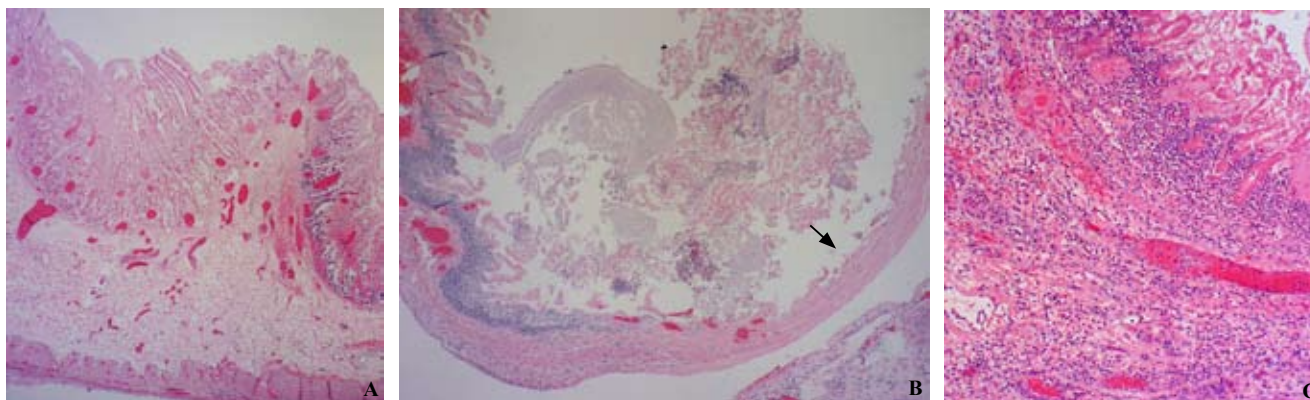
The symptoms of NEC include vomiting, feeding intolerance, abdominal distension, blood in the stools, lethargy, apnea, and temperature instability. In severe cases, it evolves into progressive systemic shock with metabolic acidosis, oliguria, hypotension and disseminated intravascular coagulation (DIC). The severity of the disease has been categorized in stages by Bell et al.<sup>[5]</sup> Stage I is defined as suspected NEC, when nonspecific symptoms such as mild abdominal distension, increased residuals, temperature instability or apnea are present. When there is macroscopic evidence of blood in the stools, stage IB is attributed. Stage II is defined as definite NEC with roentgenographic evidence of ileus and intestinal pneumatosis. Portal air, secondary metabolic acidosis, thrombocytopenia or ascites defines stage IIB. Stage III is advanced NEC with clinical signs of hypotension, metabolic acidosis, DIC, neutropenia or marked abdominal tenderness. When signs of perforation are present, the stage is IIIB.

Abdominal X-ray examination is the diagnostic procedure of choice. When NEC is suspected, serial abdominal X-ray films are recommended to check for the presence of pneumatosis intestinalis and pneumoperitoneum and for assessing disease progression. Pneumatosis intestinalis is diagnostic of NEC and is characterized by a linear bubbly pattern observed within the intestinal wall. The gas is thought to be produced by bacterial fermentation of substrates. It is present in about 85% of infants with NEC. In the most severe cases, portal air can be seen and is associated with severe bowel necrosis in about 40% of the cases. Pneumoperitoneum might be seen on a supine X-ray, where air will collect anteriorly, which has been described as a "football sign". However, a cross-table lateral or left lateral decubitus film often better demonstrate the accumulation of air outside the intestinal loops.

## Pathology and possible pathogenesis of NEC

The predominant anatomic lesion of NEC is coagulative or ischemic necrosis<sup>[6-9]</sup> (Fig. 1A, B), which most commonly involves the ileocecal region, because the blood supply of this region is far from the superior mesenteric artery. In about half of the cases, the necrosis involves both the small and large intestines, either continuous or segmental.<sup>[8,9]</sup> The affected bowel is grossly distended, lusterless and gray or greenish-gray, or dark purple or black if there is hemorrhage. The soft, fragile intestinal wall may perforate when the involvement is severe and transmural. Perforation tends to occur at the junction between normal and necrotic bowel, but it may appear in the midst of a devitalized region, and sometimes at more than one site. Gas bubbles, which may be grossly visible in the intestinal wall, involve the entire colon more commonly in the term infant than in the premature.<sup>[8]</sup>

Ischemic necrosis of the intestine can develop secondary to thromboembolism of the mesenteric arteries. However, in most patients with NEC, no occlusion of large arteries can be identified. NEC and infarction are probably different clinicopathological entities, even though both manifest coagulative necrosis. An infarct is usually single and should follow the distribution of the arterial blood supply. In contrast, NEC is basically an inflammatory process, and a venule may be the initiating site of the pathophysiology. The affected areas are often multiple, and are randomly distributed. The early histological change in surgical specimens of NEC is coagulative necrosis (Fig. 1A, B), and inflammatory cells infiltrate when the disease progresses (Fig. 1C).<sup>[9]</sup> Bacteria are important in NEC, since the disease usually does not occur before bacterial colonization of the intestine. Bacterial overgrowth in NEC seems to exceed that in other diseases with ischemic bowel.<sup>[9]</sup> Intestinal pneumatosis, the peculiar and characteristic finding seen in many cases of NEC, is not observed in infarcts. The formation of gas bubbles within the intestinal wall, most likely resulting from the fermentation of intraluminal contents by bacteria, is associated more with NEC than with any other necrotizing conditions affecting the intestine. Bacterial production of P-galactosidase, which reduces pH by fermentation of lactose, has been suggested to contribute to the development of intestinal pneumatosis.<sup>[10]</sup> However, the ability of colonizing bacteria to ferment lactose is not correlated with the production of NEC;<sup>[11]</sup> moreover, the endemic cases of NEC are not consistently associated with a single infectious agent or with a particularly virulent organism that produces highly damaging toxins or that displays great entero-invasive or entero-aggregative ability.



**Fig. 1.** Microscopic appearance of the small intestine from infants with necrotizing enterocolitis, showing areas of extensive mucosal necrosis (A), transmural necrosis (B), and inflammatory cell infiltration (C) (HE, magnification  $\times 100$ ) (arrow: transmural necrosis).

Disparate microorganisms have been isolated from the stools of NEC patients, and in some cases from both blood and stools: *Escherichia coli*, *Klebsiella*, *Enterobacter*, *Pseudomonas*, *Salmonella*, *Clostridium perfringens*, *Clostridium difficile*, *Clostridium butyricum*,<sup>[12]</sup> *coagulase-negative staphylococci*,<sup>[13]</sup> coronavirus, rotavirus, and enteroviruses.<sup>[14]</sup>

Intestinal inflammation affects about 90% of the patients with NEC and is considered an appropriate host response to tissue injury and proliferating bacteria.<sup>[9]</sup> Inflammation tends to be more severe and more conspicuous when devitalization of the bowel is gradual, in contrast to the ischemic necrosis that follows sudden occlusion of the arterial circulation, as in thromboembolism. The character of the inflammation in colitis of infectious origin differs from that in NEC.<sup>[9]</sup> Microabscesses and crypt abscesses are common in infectious colitis, but they are found in only 10% of the surgical specimens obtained from patients with NEC. Moreover, extensive necrosis beyond the inflammation is a feature of NEC that is generally absent in cases of infectious enterocolitis. Ballance et al<sup>[9]</sup> also found reparative activity of recent onset in 68% of the patients, all undergoing surgery for the first time. Regenerative changes in NEC are usually marked by a layer of cuboidal or tall epithelium with hyperchromatic nuclei, mitotic activity and without mucin, which covers granulation tissue or a partly reconstituted lamina propria with distorted, morphologically aberrant glands.<sup>[7,15]</sup>

The pathogenesis of NEC is thought to be multifactorial and is poorly understood. Intraluminal nutrient plays a role since most cases of NEC (90%) occur in infants being fed. Breast milk has been shown to provide some protection against the disease. It contains many factors, which could be responsible for this protection, such as immunoglobulin A and

G, lymphocytes and growth factors. Bacteria are also involved, since many cases often occur in clusters, and sporadic epidemics have been associated with *Klebsiella*, *E. Coli*, *Chlostridia*, *coagulase negative staphylococcus* and rotavirus.<sup>[16]</sup> Bowel ischemia is another suspected contributing factor: NEC has been associated with low Apgar scores, umbilical catheters, polycythemia, impaired aortic blood flow, exposure to cocaine, congenital heart disease such as hypoplastic left heart syndrome and truncus arteriosus. The immaturity of host defense is likely to play a significant role as well since the disease affects mostly premature infants. Most of the proposed theories on the pathogenesis were derived from the risk factors recognized by clinical observations. In recent years, there has been a considerable progress in the understanding of the disease by the successful establishment of animal models.

### Animal models of bowel necrosis induced by platelet-activated factor, lipopolysaccharide and tumor necrosis factor- $\alpha$

One of the favorite models for NEC uses young adult rats and mice injected with endotoxin (lipopolysaccharide, LPS),<sup>[17]</sup> platelet-activating factor, or paf-acether (PAF),<sup>[18,19]</sup> tumor necrosis factor- $\alpha$  (TNF),<sup>[20]</sup> or a combination of these agents. This model is technically easy and yields consistent results. The rationale for using these agents is as follows.

LPS: NEC is clearly associated with intestinal bacterial growth, since NEC usually develops following oral feeding, and oral feeding markedly increases the growth of intestinal flora, such as *E. coli*, in the gastrointestinal tract.<sup>[21]</sup> We hypothesized that gram negative intestinal flora such as *E. coli* and

their cell wall product, LPS, would play a role in the development of NEC.

PAF: Injection of LPS induces endogenous production of PAF,<sup>[22,23]</sup> systemic administration of PAF<sup>[24-26]</sup> to animals mimics symptoms and signs of shock, and PAF antagonists prevent LPS-induced shock.<sup>[26,27]</sup>

TNF: LPS induces endogenous TNF production<sup>[23,28,29]</sup> and administration of TNF causes shock and bowel injury,<sup>[30,31]</sup> whereas pretreatment of the animal with anti-TNF<sup>[31]</sup> ameliorates endotoxin shock and increases survival.

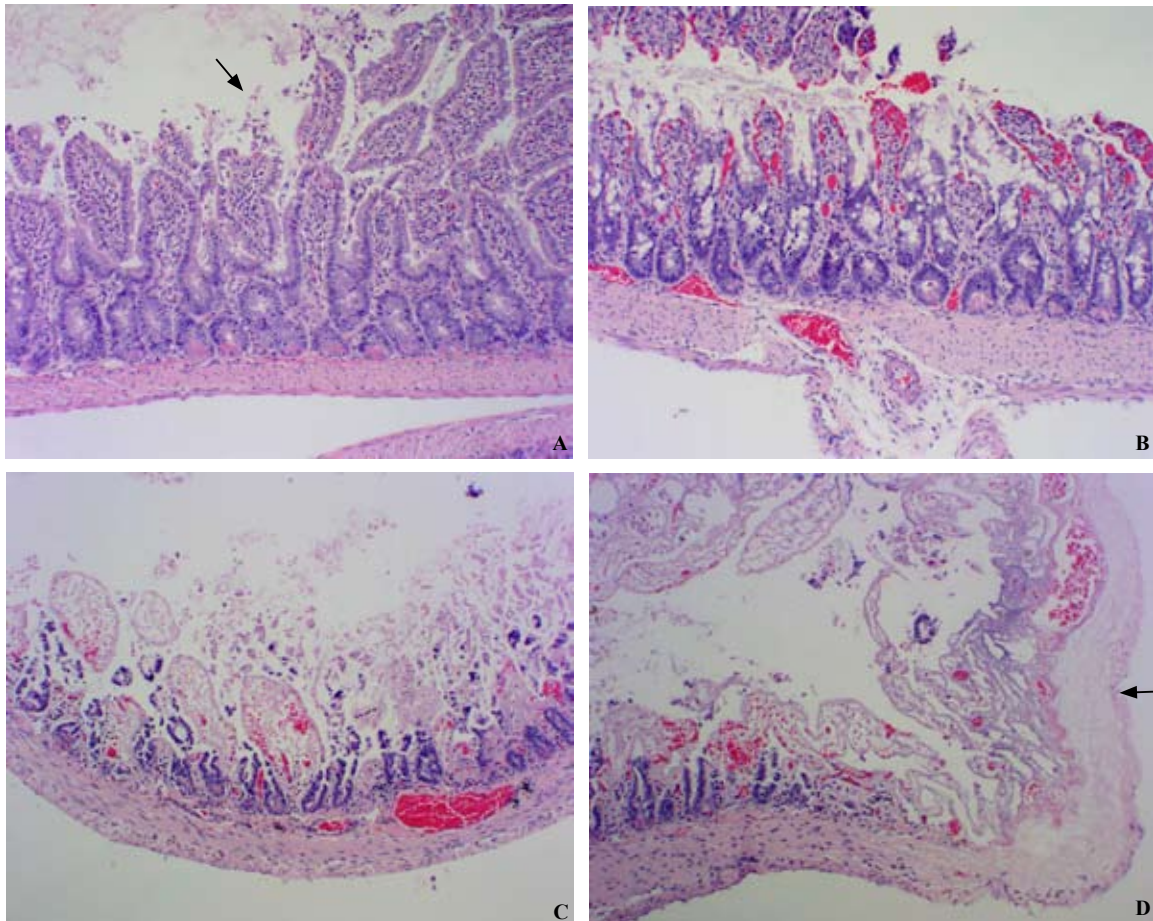
### The effect of PAF, its secondary mediators, and its synergism with LPS

PAF is an endogenous phospholipid mediator produced by inflammatory cells, endothelial cells, platelets,<sup>[24,25,32]</sup> and bacteria of the intestinal flora, such as *E. coli*.<sup>[33]</sup>

Systemic administration of PAF induces an immediate and sometimes transient hypotensive

response. With large doses, the shock becomes profound and irreversible, and intestinal necrosis develops rapidly. Early injury is usually detectable within 15 minutes. PAF is probably the most potent agent to induce intestinal injury. PAF, as little as 2.5 µg/kg, i.v., often causes small intestinal necrosis of varying degrees in the rats. Since rat platelets are refractory to PAF,<sup>[18,34]</sup> the pathogenesis of necrosis cannot be due to the thromboembolic effect of PAF. The necrosis, usually focal, involves the jejunum, ileum, especially the distal ileum, and/or cecum. With high doses, the entire small bowel can be affected. The necrosis begins at the villus tip (Fig. 2A),<sup>[18]</sup> and progresses to the villus base (Fig. 2B, C), sometimes extending to the submucosa or even transmurally (Fig. 2D).

Although LPS alone can cause intestinal injury, the required dosage is often high (>5 mg/kg). However, LPS is a potent "priming" agent for PAF: a small dose of LPS (0.5 mg/kg) acts synergistically with a low dose of PAF.<sup>[18,19,35]</sup> LPS-induced intestinal injury was blocked



**Fig. 2.** Microscopic appearance of the small intestine from rats injected with PAF (2.5 µg/kg) showing early stage of intestinal injury with loss of epithelial cells at the villus tips (A), extensive mucosal necrosis with loss of villi (B, C), and transmural necrosis (D) (HE, magnification × 100) (arrow: transmural necrosis).

by pretreatment with PAF antagonists,<sup>[17]</sup> suggesting that this effect is mediated by endogenous PAF.

Why the small intestine, especially the ileum, is sensitive to PAF action is probably due to its high content of PAF receptors (PAF-R). Using quantitative PCR, we found that the ileum has the highest number of PAF-R transcripts:  $(3.49 \pm 0.15) \times 10^7$  molecules/ $\mu$ g RNA.<sup>[36]</sup> The PAF-R content of the jejunum was only 56% of that of the ileum, and the spleen was only 30%. Other organs, e.g., the lung, kidney, heart, stomach and liver, had less than 1% of that of the ileum.<sup>[36]</sup> PAF, even at doses below those causing bowel necrosis, almost doubled PAF-R mRNA in the intestine.<sup>[36]</sup> The increase is biphasic; the second peak (at 6 hours) seems dependent on endogenous PAF and TNF.<sup>[36]</sup> In the small intestine, PAF receptor was localized mainly in epithelial cells and eosinophils of the lamina propria, although it appears that only epithelial PAF-R is readily upregulated by inflammatory stimuli like PAF.<sup>[37]</sup>

PAF also seems to be the endogenous mediator for hypoxia-induced bowel injury. It is known that decreased oxygen delivery to the mesenteric circulation, as seen with asphyxia,<sup>[38]</sup> cyanotic congenital heart disease,<sup>[39]</sup> decreased mesenteric flow associated with intrauterine growth retardation,<sup>[40]</sup> and maternal cocaine use,<sup>[41]</sup> are associated with an increased risk of NEC in human infants. We found that when young adult (25- to 30-day-old) male Sprague-Dawley rats were exposed to acute severe hypoxia (by exposure to 100% nitrogen for 2 minutes), or to subacute moderate hypoxia (in a 10% oxygen atmosphere for 15 or 30 minutes), plasma levels of PAF were markedly elevated.<sup>[42]</sup> Thirty minutes of moderate hypoxia produced mild to moderate ischemic bowel necrosis, with no evidence of necrosis in any other organs (Two minutes of severe hypoxia were not sufficient to induce bowel injury). The bowel injury was prevented by two structurally unrelated PAF antagonists, WEB 2086 and SRI 63-441. We concluded that hypoxia results in a rapid increase in endogenous PAF levels and that PAF is a mediator of hypoxic intestinal injury. Furthermore, when young adult male rats were treated with combined insults of LPS (2 mg/kg *Salmonella typhosa* endotoxin, i.v.) and hypoxia (5% oxygen for 90 minutes), the intestinal injury that developed was also ameliorated by PAF antagonists, either WEB 2086 or SRI 63-441.<sup>[43]</sup> Thus, PAF is an important mediator in LPS- and hypoxia-induced bowel necrosis (Since in these studies we assessed the biological activity, rather than chemical analysis of PAF, we could not differentiate PAF from PAF-like phospholipids; the latter also bind to PAF receptor and have effects that are much like those of PAF<sup>[44]</sup>).

PAF has a short half-life in the blood, being rapidly

degraded by serum acetylhydrolase (PAF-AH) into the biologically inactive lyso-PAF.<sup>[45-47]</sup> However, the *in vivo* action of PAF is prolonged, partly due to the fact that PAF induces its own production in tissues.<sup>[48]</sup> When PAF antagonists were given before PAF challenge, the production of PAF (and PAF-like phospholipids) is markedly reduced.<sup>[17,48]</sup> Although PAF is a vasodilator *in vitro*,<sup>[49]</sup> high doses cause sustained vasoconstriction of the splanchnic bed *in vivo*.<sup>[49,50-52]</sup> Administration of antagonists to peptide leukotrienes<sup>[19,51]</sup> or alpha blockers<sup>[51]</sup> *in vivo* prevents PAF-induced intestinal injury, but often do not reverse the hypotension.

The complement system, especially C5, may also participate in producing NEC, since the injection of PAF or TNF/LPS activates the complement system *in vivo*,<sup>[53,54]</sup> and C5-deficient mice are protected from TNF/LPS- or PAF-induced injury.<sup>[53]</sup>

### Roles of NF- $\kappa$ B and chemokine MIP-2/CXCL2

Many inflammatory cytokines have been found to be released in NEC,<sup>[55]</sup> suggesting their roles in the disease. We have found that nuclear factor  $\kappa$ B (NF- $\kappa$ B), a central transcription factor in the regulation of many proinflammatory cytokines, is activated in rat intestine following PAF injection.<sup>[56,57]</sup> The activated NF- $\kappa$ B is composed mainly of p50 homodimer.<sup>[57]</sup> LPS also activates NF- $\kappa$ B, but mostly the p50-p65 dimer,<sup>[58]</sup> and its effect is partly mediated via endogenous PAF and TNF.<sup>[58]</sup> Preliminary experiments show that blocking NF- $\kappa$ B with NF- $\kappa$ B essential modulator-binding domain (NBD) peptide<sup>[59]</sup> attenuates PAF-induced injury.

Neutrophils are thought to play an important role in NEC. In the PAF-induced bowel necrosis model, neutrophils mediate bowel injury, hypotension, hemoconcentration<sup>[60]</sup> and NF- $\kappa$ B activation.<sup>[57]</sup> The recruitment of neutrophils toward sites of inflammation is regulated by chemokines. Following PAF injection, we have found that CXCL2 (macrophage inflammatory protein-2, MIP-2), a major chemokine for neutrophils, is produced in the intestinal tissues and its levels are increased in the plasma.<sup>[61]</sup> Furthermore, we found that antibodies against CXCL2 blocked PAF-induced bowel injury and hypotension.<sup>[61]</sup> It is possible that stressed enterocytes produce CXCL2, which causes local neutrophil recruitment during NEC. These then adhere to the mesenteric endothelium, releasing further inflammatory mediators and causing further intestinal inflammation and necrosis.

### TNF and its interaction with PAF and LPS

TNF has many proinflammatory actions,<sup>[62-64]</sup> such as inducing leukocyte and endothelial adhesion molecules,

activating polymorphonuclear leukocytes (PMNs) and endothelial cells, and causing production of other cytokines, including TNF itself,<sup>[62]</sup> eicosanoids,<sup>[63]</sup> and PAF.<sup>[65]</sup> The splanchnic bed is a major source of TNF production *in vivo*.<sup>[66,67]</sup> In normal intestine, TNF is constitutively expressed at very low levels within Paneth cells.<sup>[68]</sup> During the acute stage of NEC, TNF gene transcripts markedly increase not only within Paneth cells, but also in lamina propria eosinophils, and infiltrating (but not resident) macrophages.<sup>[69]</sup> Paneth cells are also rich in group IIA phospholipase A2 (PLA2-IIA),<sup>[70]</sup> an acute phase protein possibly involved in PAF synthesis, which is also upregulated by PAF.<sup>[71]</sup>

LPS (2 mg/kg) and PAF (1 µg/kg), at doses below those causing shock and intestinal injury, stimulate TNF gene expression and protein production in the rat's liver and small intestine, predominantly in the ileum.<sup>[67]</sup> LPS may induce TNF production via both PAF-dependent and PAF-independent pathways, as WEB-2086, a PAF antagonist, only partially blocked LPS-induced TNF mRNA formation.

Intravenous injection of TNF (1 mg/kg) induces hypotension and mild intestinal injury in rats.<sup>[20]</sup> However, when TNF (0.5 mg/kg) is injected together with LPS (200 µg/kg) to rats<sup>[20]</sup> or mice,<sup>[54]</sup> a profound shock and severe intestinal necrosis develop. PAF may be the endogenous mediator for TNF/LPS, since PAF was detected after administration of TNF/LPS,<sup>[20]</sup> and pretreatment with a PAF receptor antagonist protects mice from shock induced by TNF/LPS, intestinal injury, and death.<sup>[20]</sup>

The transcription of TNF is regulated by transcription factors, including NF-κB.<sup>[72]</sup> In turn, TNF activates NF-κB *in vitro*<sup>[72,73]</sup> and *in vivo*,<sup>[56]</sup> a pathway that may be involved in TNF's self-activation.

### Initial events after PAF administration: PMN activation, PMN-endothelial cell adhesion and mucosal barrier breakdown

One of the earliest events following PAF challenge is probably PMN activation and PMN-endothelial adhesion. PMN-depletion markedly reduces PAF-induced bowel injury.<sup>[53,59]</sup> The major adhesion molecule involved in the PAF effect is leukocyte β2-integrin, especially CD11b/CD18, since pretreatment with anti-CD11b or anti-CD18 antibody largely prevents PMN influx (indicated by a marked elevation of intestinal myeloperoxidase content) as well as PAF-induced bowel injury.<sup>[59]</sup> Anti-CD18 antibody also prevents the PAF-induced increase in endothelial<sup>[74]</sup> and mucosal<sup>[75]</sup> permeability. P-selectin may also play a role, as P-selectin-deficient mice are protected. Fucoidin-treated ICAM-1 deficient mice are also protected from the

adverse effects of PAF,<sup>[76]</sup> although fucoidin (a potent inhibitor of selectins) alone shows no protective effect.<sup>[75,76]</sup> Yet extravascular PMN infiltration is not found by histological examination, indicating that PMN transmigration into tissues may be a late process.

A PAF challenge increases gut mucosal permeability.<sup>[77]</sup> PAF alters the cytoskeletal structure of the intestinal epithelium and induces tyrosine phosphorylation of E-cadherin, an epithelial membrane component of the *zona adherens*.<sup>[77]</sup> In NEC, this action of PAF may facilitate the entry of bacterial products including LPS, from the gut lumen into the tissues, triggering the inflammatory cascade. Bacterial toxins from the intestinal lumen are essential for the development of bowel injury following PAF challenge, since germ-free rats do not show signs of tissue damage, and this protection is lost when the animal is primed with exogenous LPS.<sup>[78]</sup> Furthermore, conventional rats, treated with combined antibiotics, which markedly decrease intestinal bacteria, are protected to a large extent from the injurious effects of PAF.<sup>[78]</sup> and endotoxin-resistant mice are protected from PAF-induced intestinal injury.<sup>[79]</sup> The actions of PAF and bacterial toxins (e.g., LPS) on intestinal injury are synergistic.<sup>[17,80]</sup>

### Reactive oxygen species (ROS): effector of injury?

The final effector of PAF-caused injury is most likely ROS. ROS can be released by activated PMNs, but the major source of ROS in the intestine is probably the xanthine dehydrogenase/xanthine oxidase complex (XD/XO).<sup>[81]</sup> XD, the precursor of XO, is abundant in normal intestinal villus epithelium.<sup>[82,83]</sup> During ischemia/reperfusion, XD is converted to XO. XO uses molecular oxygen as an electron receptor and thereby generates superoxide, which, in the presence of iron, forms the potent tissue damaging OH<sup>•</sup>. The produced ROS has been proposed to mediate reperfusion injury.<sup>[81]</sup> The small intestine is one of the highest sites for XD/XO activity in rats. Normally, the total XD+XO content (XD/XO ratio approximately 80:20) is higher in the jejunum than in the ileum.<sup>[82]</sup> Following PAF challenge, however, it is the ileum that shows the most dramatic XD to XO conversion (more than 2 fold increase in XO).<sup>[82]</sup> This change is rapid, detected at 15 minutes, and by 60 minutes, more than 60% of the total XD+XO activity is converted to XO. The conversion takes place mainly in the villus epithelial cells, and the major pathway is probably via activated protease,<sup>[82]</sup> possibly released from activated inflammatory cells such as PMN's. The central role of XO and ROS in causing the injury is supported by the observation that pretreatment with allopurinol,<sup>[82,84]</sup> a

xanthine oxidase inhibitor, largely prevents PAF-induced bowel necrosis. Infusion of superoxide dismutase plus catalase also alleviates the injury.<sup>[84]</sup>

### Endogenous protective mechanisms in the intestine: nitric oxide (NO) and neuronal nitric oxide synthase (nNOS)

There are 3 NOS isoforms: the constitutive neuronal (type I) nNOS, the endothelial (type III) eNOS, and the inducible (type II) iNOS.<sup>[85]</sup> More than 90% of the total NOS in the small intestine are nNOS.<sup>[86]</sup> Although iNOS is constitutively present, it accounts for less than 10% of the total NOS activity.<sup>[86, 87]</sup> PAF rapidly decreases intestinal nNOS protein, mRNA, and enzyme activity,<sup>[86]</sup> but has little effect on iNOS.<sup>[87]</sup> The protective role of NO is supported by the following observations: (1) the degree of injury is inversely related to the nNOS activity; (2) NOS inhibitor L-NAME aggravates PAF-induced necrosis,<sup>[88]</sup> (3) iNOS inhibitors are protective only when there is "sufficient" nNOS activity;<sup>[87]</sup> (4) NO donors significantly reduce PAF-induced bowel injury;<sup>[87]</sup> and (5) tetrahydrobiopterin (BH4), a nNOS cofactor essential for its action, protects rats from PAF-induced intestinal ischemia and necrosis.<sup>[89]</sup> NO may help to maintain the integrity of the mucosal barrier and the microvasculature, to increase blood flow, and to inhibit leukocyte adhesion.<sup>[90]</sup>

Endogenous NO also protects against hypoxia-induced intestinal injury.<sup>[91,92]</sup> In a related study, inhibition of endogenous NO production with L-arginine analogs significantly worsened the bowel injury produced by 90 minutes of 10% oxygen exposure. PAF levels were significantly elevated in the intestines of animals exposed to hypoxia and a NO synthase inhibitor, and the intestinal injury seen in these animals was prevented with the PAF antagonist WEB 2086. In the vascular endothelium, NO synthesized from L-arginine by the constitutive form of nitric oxide synthase (eNOS) limits neutrophil adhesion, promotes microvascular integrity, and maintains basal vasodilator tone.<sup>[93]</sup>

### Neonatal model of NEC: role of hypoxia, enteral feeding, bacterial and endogenous PAF

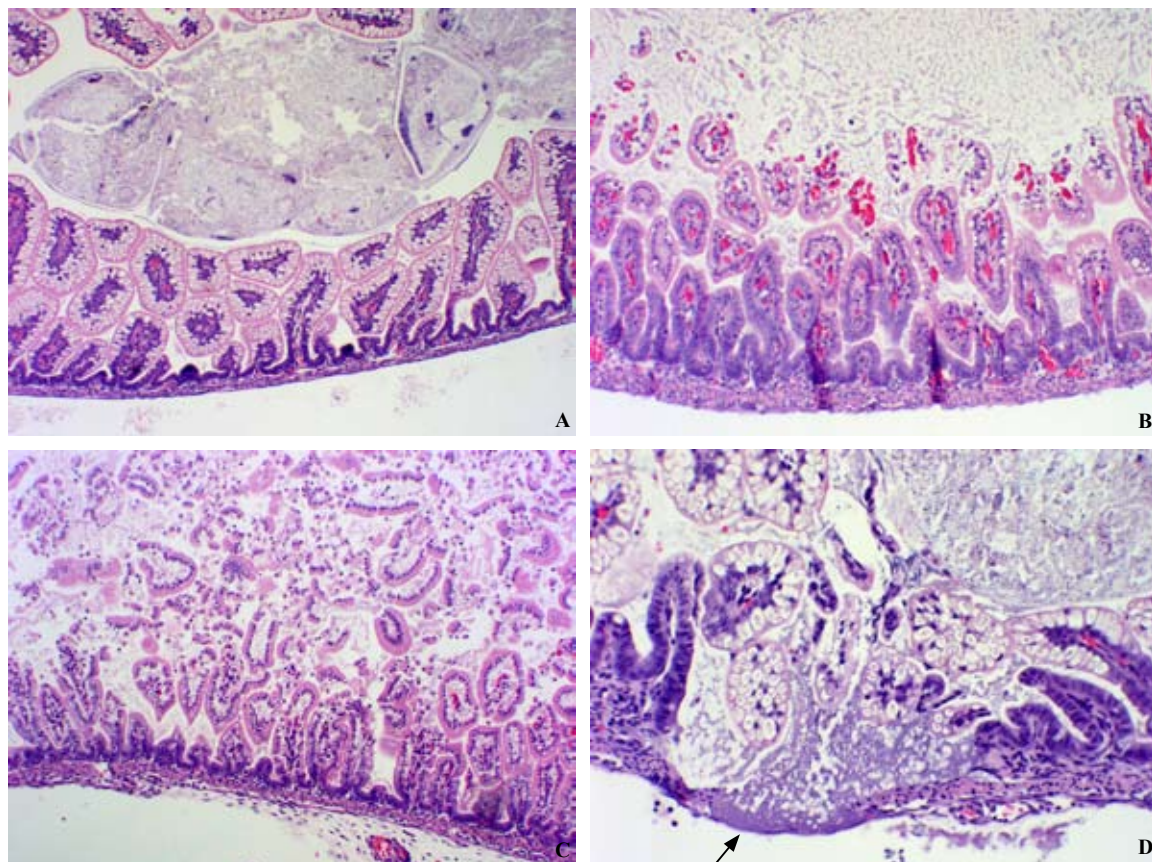
The PAF model using young adult rats and mice is simple and reproducible, but it lacks a critical feature of human NEC, i.e., the newborn age and prematurity. A neonatal model of Barlow et al,<sup>[94,95]</sup> first described in 1972, most closely resembles human NEC.<sup>[94-96]</sup> We modified Barlow's model and further characterized the pathologic findings.<sup>[97]</sup> Neonatal rats delivered via abdominal incision were maintained in a neonatal

incubator and received the following stresses: (1) artificial formula feedings (0.1 ml every 3 hours via orogastric tube, 200 cal/kg per day, advanced as tolerated); (2) asphyxia (100% N<sub>2</sub> for 50 seconds twice daily); and (3) *E. coli* inoculation (1×10<sup>9</sup> organisms/d via orogastric tube) (In recent experiments commensal gut bacteria were used instead of *E. coli*). NEC developed in more than 75% of the neonatal rats exposed to hypoxia, formula feeding and bacteria. Pathologic findings were similar to human NEC. Grossly, the intestine was hemorrhagic, with friable, occasionally segmental lesions, but often involving most of the intestinal length. The necrosis began at the villus tip, may extend to the submucosa (Fig. 3B, 3C) and sometimes through the entire thickness (Fig. 3D).

When neonatal animals stressed with asphyxia, formula feeding, and oral bacterial inoculation were pretreated with the PAF receptor antagonists WEB 2170 (a gift from Boehringer Ingelheim, Mainz, Germany) (10 mg/kg q am/30 mg/kg q pm), the incidence of NEC was reduced from 14/18 (control group) to 3/17. The death rate was also reduced to 6/17, compared with 17/18 in the controls.<sup>[98]</sup> A 4-fold higher WEB 2170 dosing regimen did not alter the incidence of NEC, presumably because of an agonist effect on the PAF receptor at very high doses.<sup>[98]</sup> Intestinal PAF concentrations were elevated (270±80 pg/g) in animals stressed with asphyxia, formula feeding, and bacterial inoculation compared with age-matched, healthy, maternally fed controls (70 ±50 pg/g, *P*<0.05). When neonatal rats were treated with the PAF degrading enzyme, PAF-AH, as enteral supplementation in doses approximately 10-fold higher than found in human breast milk, the incidence of NEC was reduced from 19/26 in controls to 6/26 (*P*<0.05).<sup>[99]</sup> In addition, PAF-AH (human, recombinant protein) was identified by immunohistochemistry throughout the intestinal tract and remained functionally active for greater than 24 hours after dosing.<sup>[99]</sup> Interestingly, there was no measurable human PAF-AH in the circulation of animals using a sensitive monoclonal antibody/ELISA technique.<sup>[99]</sup> In a neonatal piglet model of NEC induced by hypoxia and LPS, WEB 2170 was found to ameliorate the hemodynamic change as well as the intestinal injury.<sup>[100]</sup> Taken together, these observations support the hypothesis that endogenous PAF acts as a critical mediator in this neonatal rat model of NEC.

### Protective role of probiotics: the "magic bullet"?

The colonization of the gut microflora is established shortly after birth, and is important to the host regarding metabolic functions and resistance to bacterial invasion. Healthy breast-milk fed neonates are colonized with multiple flora including a predominance of the



**Fig. 3.** Necrotizing enterocolitis in neonatal rats subjected to asphyxia, formula feeding, and bacteria ingestion. **A:** neonatal small intestine without injury. **B & C:** small intestine showing necrosis with partial (**B**) or complete (**C**) loss of villi. **D:** area of transmural necrosis (HE, magnification  $\times 250$ ) (arrow: transmural necrosis).

probiotic *Bifidobacteria* and *Lactobacilli*, whereas coliforms, enterococci and bacteroides predominate in formula-fed infants.<sup>[101]</sup> To examine the protective role of probiotic bacteria, we treated neonatal animals with  $10^9$  *Bifidobacteria infantis* organisms every day and evaluated for the development of experimental NEC (as described above), endotoxin translocation, mucosal permeability, and PLA<sub>2</sub>-II mRNA expression. *Bifidobacteria infantis* supplementation reduced the incidence of NEC (7/24 vs 19/27 control,  $P < 0.05$ ) but did not alter the colonization pattern of gram-negative organisms.<sup>[102]</sup> *Bifidobacteria infantis* were identified in the stool and intestinal lumen of treated animals but absent in the controls. In addition, *Bifidobacteria infantis* treatment markedly reduced PLA<sub>2</sub>-II gene expression in intestinal tissue ( $42 \pm 29$  mol/ $\mu$ g tissue vs  $802 \pm 320$  control,  $P < 0.01$ ) but had no effect on mucosal permeability.<sup>[102]</sup> The results suggest that *Bifidobacteria infantis* reduces the incidence of NEC by altering PAF metabolism and bacterial translocation.

Recent clinical studies showed considerable promise of administration of probiotics as a preventive measure for NEC. In one study,<sup>[103]</sup> 367 very low birth weight

(VLBW) ( $< 1500$  g) neonates who had survived beyond 7 days were randomized into 2 groups. The control group was fed with breast milk alone, and the study group also received inforan (*Lactobacillus acidophilus* and *Bifidobacterium infantis*) as supplement. The incidence of NEC of stage II or more was significantly lower in the study group than in the control group. The incidence of death was also lower (9 of 180 vs 24 of 187). There were 6 cases of severe NEC (stage III) in the control group and none in the study group. In another study,<sup>[104]</sup> VLBW ( $< 1500$  g) infants were treated with oral probiotics mixture of *Bifidobacteria infantis*, *Streptococcus thermophilus*, and *Bifidobacteria bifidus*. Fifteen babies out of 73 in the control group developed NEC and 3 died. The incidence of NEC and its severity were reduced in the 72 infants in the study group. No death occurred in the study group.

The protective action of probiotics is probably more than a simple "bacterial warfare" or a competition between the probiotics and pathogens within the gut lumen. Probiotics have been shown to enhance host innate immunity, both mucosal and systemic, by producing specific polysaccharides.<sup>[105]</sup> Despite the



reported benefits in treating various diseases, the safety of administering live probiotics to premature infants remains a concern, especially after the report of 2 cases of *Lactobacillus* sepsis associated with probiotic therapy in children.<sup>[106]</sup> Recent studies have demonstrated a protective effect of heat-killed probiotics against DDS-induced colitis,<sup>[107]</sup> suggesting an alternative way to administer probiotics. Understanding the intestinal microbe ecosystem and its interaction with the luminal nutritional environment (especially regarding maternal milk) may shed light on the pathogenesis of NEC and lead to its prevention and treatment. Much remains to be investigated in this new field, such as the strain-specific effect, dosing regimen and contraindications.

### Correlation of human NEC with experimental NEC

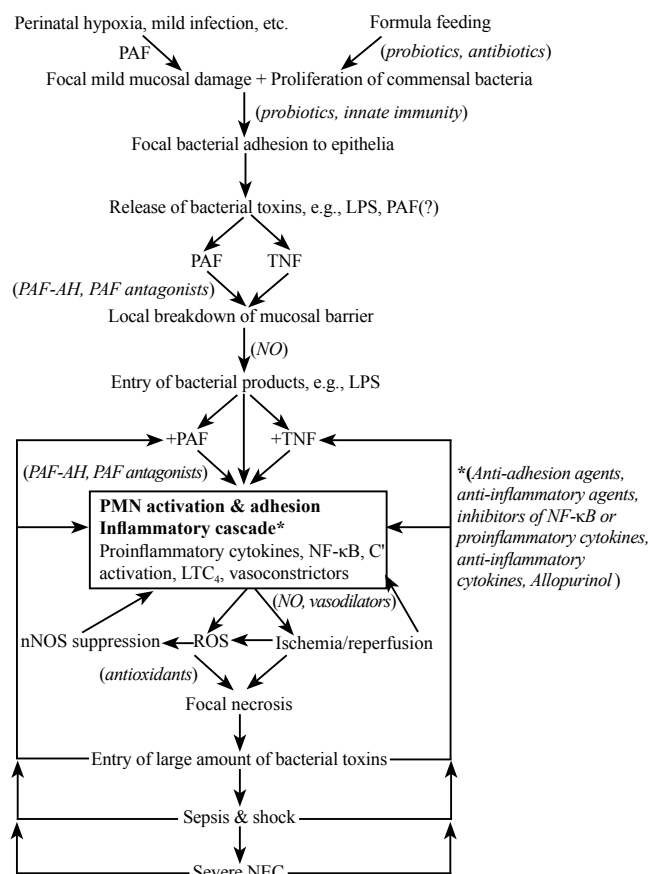
Experimental evidence strongly supports the role of PAF, TNF and toxic products of intestinal commensal bacteria (e.g., LPS), in the pathogenesis of acute ischemic bowel necrosis and in the neonatal rat model of NEC. Some data from human studies suggest a similar pathophysiology in neonatal NEC. Local and systemic PAF concentrations are elevated in neonates with NEC, and feeding alone promotes PAF production. We and other investigators found higher circulating plasma levels of PAF and/or PAF-like phospholipid in NEC patients compared with age-matched, illness-matched controls.<sup>[108,109]</sup> These NEC patients also had higher circulating TNF- $\alpha$  levels<sup>[108]</sup> and lower plasma PAF-AH activity than control babies. Enteral feeding itself caused elevations of circulating PAF levels in a significant percentage of preterm infants,<sup>[110]</sup> although the circulating PAF-AH activity was not affected by the feeding regimen. Circulating PAF may not adequately reflect the activity in the local environment (intestinal lumen/mucosa), but stool PAF concentrations also increased with feedings.<sup>[111]</sup> Fourteen days after feedings were begun, the PAF levels were approximately 3-fold higher than prefeeding values ( $1028 \pm 244$  pg/g vs  $357 \pm 76$  pg/g,  $P < 0.05$ ).<sup>[110]</sup> Stool samples from seven patients with NEC (stage II or III) had the highest levels, with a mean PAF concentration 8-fold higher than controls ( $2484 \pm 154$  pg/g).<sup>[111]</sup>

Several factors may predispose newborns and especially premature infants to NEC, e.g., immature gastrointestinal host defense, dysfunctional mesenteric blood flow autoregulation, and low PAF-AH.<sup>[47,112]</sup> Although plasma PAF-AH activity is lower in NEC patients than in the controls,<sup>[108]</sup> PAF-AH activity is low in newborns as a group, reaching normal adult

values at 6 weeks of life.<sup>[113]</sup> Infants fed with breast milk (containing significant PAF-AH activity) have a much lower risk of NEC than infants fed with formula (without measurable PAF-AH activity).<sup>[114]</sup> In animal experiments, upregulation of PAF-AH can prevent ischemic bowel necrosis following exogenous PAF infusion.<sup>[115]</sup> These data strongly support the role of PAF in neonatal NEC and suggest that low neonatal PAF-AH activity may in part explain why NEC predominates in the neonates. The role of toxins from intestinal commensal bacteria in the development of bowel injury is attested by the observations that germ-free rats do not develop bowel injury after PAF challenge.<sup>[78]</sup> The absence of NEC in the human fetus (in germ-free environment) may represent a similar situation. Aberrant composition of intestinal microbiota in premature infants may contribute to the pathogenesis of NEC.

### Proposed mechanism for the pathogenesis of NEC (Fig. 4)

The initial insult in the pathogenesis of NEC could be



**Fig. 4.** Flow diagram of the proposed pathogenesis of NEC (inhibitors are in italics and within parentheses).

perinatal hypoxia or a mild postnatal infection, either of which results in mild mucosal damage. Following formula feeding there may be aberrant colonization of intestinal microbiota and their excessive proliferation. Because of the immature "mucosal barrier" and inadequate probiotic colonization, the commensal bacteria may attach to the damaged intestinal epithelium, thus eliciting endogenous production of PAF (and PAF-like phospholipids) and TNF. Major sources of PAF may be epithelial cells, lamina propria cells, endothelial cells and commensal bacteria. In the mature intestine, a normal mucosal barrier and a robust innate immune response probably prevent any deleterious action on the epithelium. However, in immature and mildly damaged mucosa, the close proximity of bacteria and intestinal epithelial cells may facilitate transcellular permeation of PAF and bacterial toxins such as LPS into the mucosa. If PAF-AH is low (as in premature infants), PAF, which increases the intestinal epithelial permeability *in vivo*, may accumulate locally, leading to focal mucosal "leak" and local entry of commensal bacteria or their toxic products. PAF may then synergize with LPS and/or TNF, reaching the threshold necessary to trigger a cascade of inflammatory events: PMN activation and adhesion to venular endothelium, increase in vascular permeability, complement activation, NF- $\kappa$ B activation, induction of proinflammatory cytokines and adhesion molecules, and release of ROS and other inflammatory mediators, and PAF and TNF themselves. Eventually, vasoconstriction occurs, leading to ischemia and subsequent reperfusion. Activation of xanthine oxidase with massive reactive oxygen species production occurs as a consequence of ischemia and/or protease activation. The final result depends on the balance between the injurious mechanisms (inflammatory mediators, cytokines, ischemia, ROS) and the protective mechanisms (nNOS, probiotics, innate immunity and anti-inflammatory cytokines such as IL-10). An imbalance favoring the former will result in serious breakdown of the mucosal barrier and bacterial entry, thereby launching a self-perpetuating vicious cycle, leading to shock, sepsis and sometimes death.

## Acknowledgements

We thank Dr. H. Heuer, Boehringer Ingelheim, Mainz, Germany, for his generous gift of WEB 2086 and WEB 2170.

**Funding:** This work was supported by NIH grants RO1 DK 34574, HD 31840, HD00999, KO8 HD044558 grants and an IDPH grant (IDP).

**Ethical approval:** All animal studies were approved by the

Institutional Animal Care and Use Committee.

**Competing interest:** None.

**Contributors:** HW wrote the first draft of this paper. All authors contributed to the intellectual content and approved the final version.

## References

- 1 Kliegman RM, Fanaroff AA. Necrotizing enterocolitis. *N Engl J Med* 1984;310:1093-1103.
- 2 Stoll BJ. Epidemiology of necrotizing enterocolitis. *Clin Perinatol* 1994;21:205-218.
- 3 De Curtis M, Paone C, Vetrano G, Romano G, Paludetto R, Ciccimarra F. A case control study of necrotizing enterocolitis occurring over 8 years in a neonatal intensive care unit. *Eur J Pediatr* 1987;146:398-400.
- 4 Hollwarth ME. Necrotizing enterocolitis: an editorial. *Acta Paediatr (Suppl)* 1994;396:401.
- 5 Bell MJ, Ternberg JL, Feigin RD, Keating JP, Marshall R, Barton L, et al. Neonatal necrotizing enterocolitis. *Ann Surg* 1978;187:1-7.
- 6 Benirschke K. Pathology of neonatal enterocolitis. In: Moore TD, eds. *Necrotizing enterocolitis in the newborn infant: report of the 68th Ross Conference on Pediatric Research*. Columbus: Ross Laboratories, 1974: 29-30.
- 7 DeSa DJ. The spectrum of ischemic bowel disease in the newborn. *Perspect Pediatr Pathol* 1976;3:273-309.
- 8 Polin RA, Pollack PF, Barlow B, Wiqger HJ, Slovis TC, Santulli TV, et al. Necrotizing enterocolitis in full-term infants: a case-control study. *J Pediatr* 1976;89:460-462.
- 9 Ballance WA, Dahms BB, Shenker N, Kliegman RM. Pathology of neonatal necrotizing enterocolitis: a ten-year experience. *J Pediatr* 1990;117:S6-13.
- 10 Carbonaro CA, Clark DA, Elseviers D. A bacterial pathogenicity determinant associated with necrotizing enterocolitis. *Microb Pathog* 1988;5:427-436.
- 11 Gupta S, Morris JG, Panigrahi P, Nataro JP, Glass RI, Gewolb IH. Endemic enterocolitis: lack of association with a specific infectious agent. *Pediatr Infect Dis J* 1994;13:728-734.
- 12 Kliegman RM, Fanaroff AA, Izant R. Clostridia as pathogens in necrotizing enterocolitis. *J Pediatr* 1979;95:287-289.
- 13 Mollitt DL, Tepas JJ, Talbert JL. The role of coagulase negative staphylococcus in neonatal necrotizing enterocolitis. *J Pediatr Surg* 1988;23:60-63.
- 14 Rotbart HA, Nelson WL, Glode MP, Triffon TC, Koqut SJ, Yolken RH, et al. Neonatal rotavirus-associated necrotizing enterocolitis: case control study and prospective surveillance during an outbreak. *J Pediatr* 1988;112:87-93.
- 15 Joshi VV, Winston YE, Kay S. Neonatal necrotizing enterocolitis: histologic evidence of healing. *Am J Dis Child* 1973;126:113-116.
- 16 Boccia D, Stolfi I, Lana S, Moro ML. Nosocomial necrotizing enterocolitis outbreaks: epidemiology and control measures. *Eur J Pediatr* 2001;160:385-391.
- 17 Hsueh W, Gonzalez-Crussi F, Arroyave JL. Platelet-activating factor: an endogenous mediator for bowel necrosis in endotoxemia. *FASEB J* 1987;1:403-405.
- 18 Gonzalez-Crussi F, Hsueh W. Experimental model of ischemic bowel necrosis. The role of platelet-activating

- factor and endotoxin. *Am J Pathol* 1983;112:127-135.
- 19 Hsueh W, Gonzalez-Crussi F, Arroyave JL. Platelet-activating factor-induced ischemic bowel necrosis. An investigation of secondary mediators in its pathogenesis. *Am J Pathol* 1986;122:231-239.
- 20 Sun XM, Hsueh W. Bowel necrosis induced by tumor necrosis factor in rats is mediated by platelet-activating factor. *J Clin Invest* 1988;81:1328-1331.
- 21 Brown EG, Ainbender E, Henley WL, Hodes HL. Etiologic role of bacteria and intestinal function. In: Brown EG, Sweet AY, eds. Neonatal necrotizing enterocolitis. New York: Grune & Stratton, 1980: 69-100.
- 22 Feuerstein G, Hallenbeck JM. Prostaglandins, leukotrienes, and platelet-activating factor in shock. *Annu Rev Pharmacol Toxicol* 1987;27:301-313.
- 23 Bone RC. The pathogenesis of sepsis. *Ann Intern Med* 1991; 115:457-469.
- 24 Benveniste J. Paf-acether, an ether phospholipid with biological activity. *Prog Clin Biol Res* 1988;282:73-85.
- 25 Hanahan DJ. Platelet activating factor: a biologically active phosphoglyceride. *Annu Rev Biochem* 1986;55:483-509.
- 26 Handley DA. Platelet-activating factor as a mediator of endotoxin-related diseases. In: Handley DA, Saunders RN, Houlihan WJ, Tornesch JC, eds. Platelet-activating factor in endotoxin and immune diseases. New York and Basel: Marcel Dekker, 1990: 451-495.
- 27 Toth PD. The biological effects of PAF antagonists on endotoxemia. In: Handley DA, Saunders RN, Houlihan WJ, Tornesch JC, eds. Platelet-activating factor in endotoxin and immune diseases. New York and Basel: Marcel Dekker, 1990: 589-608.
- 28 Beutler B, Cerami A. Tumor necrosis, cachexia, shock, and inflammation: a common mediator. *Annu Rev Biochem* 1988;57:505-518.
- 29 Zanetti G, Heumann D, Gerain J, Kohler J, Abbet P, Barra C, et al. Cytokine production after intravenous or peritoneal gram-negative bacterial challenge in mice. Comparative protective efficacy of antibodies to tumor necrosis factor-alpha and to lipopolysaccharide. *J Immunol* 1992;148:1890-1897.
- 30 Tracey KJ, Beutler B, Lowry SF, Merryweather J, Wolpe S, Milsark IW, et al. Shock and tissue injury induced by recombinant human cachectin. *Science* 1986;234:470-474.
- 31 Tracey KJ, Fong Y, Hesse DG, Manogue KR, Lee AT, Kuo GC, et al. Anti-cachectin/TNF monoclonal antibodies prevent septic shock during lethal bacteraemia. *Nature* 1987;330:662-664.
- 32 Snyder F. Platelet-activating factor and related acetylated lipids as potent biologically active cellular mediators. *Am J Physiol* 1990;259:C697-708.
- 33 Denizot Y, Dassa E, Benveniste J, Benveniste J. Paf-acether production by *Escherichia coli*. *Biochem Biophys Res Commun* 1989;161:939-943.
- 34 Sanchez-Crespo M, Alonso F, Inarrea P, Alvarez V, Egado J. Vascular actions of synthetic PAF-acether (a synthetic platelet-activating factor) in the rat: evidence for a platelet independent mechanism. *Immunopharmacology* 1982;4:173-185.
- 35 Hsueh W, Gonzalez-Crussi F, Arroyave JL, Anderson RC, Lee MC, Houlihan WJ. Platelet activating factor-induced ischemic bowel necrosis: the effect of PAF antagonists. *Eur J Pharmacol* 1986;123:79-83.
- 36 Wang H, Tan XD, Chang H, Gonzalez-Crussi F, Remick DG, Hsueh W. Regulation of platelet-activating factor receptor gene expression *in vivo* by endotoxin, platelet-activating factor and endogenous tumour necrosis factor. *Biochem J* 1997;322:603-608.
- 37 Wang H, Tan XD, Chang H, Huang W, Gonzalez-Crussi F, Hsueh W. Platelet-activating factor receptor mRNA is localized in eosinophils and epithelial cells in rat small intestine: regulation by dexamethasone and gut flora. *Immunology* 1999;97:447-454.
- 38 Wiswell T, Robertson C, Jones T, Tuttle DJ. Necrotizing enterocolitis in full-term infants: a case-control study. *Am J Dis Child* 1988;142:532-535.
- 39 Leung M, Chau K, Hui P, Tan AY, Chan FC, Lai CL, et al. Necrotizing enterocolitis in neonates with symptomatic congenital heart disease. *J Pediatr* 1988;113:1044-1046.
- 40 Hackett GA, Campbell S, Gamsu H, Cohen-Overback T, Pearce JM. Doppler studies in the growth retarded fetus and prediction of neonatal necrotizing enterocolitis, haemorrhage, and neonatal morbidity. *Br Med J* 1987;294:13-16.
- 41 Czyrko C, Del Pin CA, O'Neill JA, Peckham GJ, Ross AJ 3rd. Maternal cocaine abuse and necrotizing enterocolitis: outcome and survival. *J Pediatr Surg* 1991;26:414-421.
- 42 Caplan MS, Sun XM, Hsueh W. Hypoxia causes ischemic bowel necrosis in rats: the role of platelet-activating factor (PAF-acether). *Gastroenterology* 1990;99:979-986.
- 43 Caplan M, Kelly A, Hsueh W. Endotoxin and hypoxia-induced intestinal necrosis in rats: the role of platelet activating factor. *Pediatr Res* 1992;31:428-434.
- 44 Lloberas N, Torras J, Herreroi-Fresneda I, Crazado JM, Riera M, Hurtado I, et al. Postischemic renal oxidative stress induces inflammatory response through PAF and oxidized phospholipids. Prevention by antioxidant treatment. *FASEB J* 2002;16:908-910.
- 45 Stafforini DM, Elstad MR, McIntyre TM, Zimmerman GA, Prescott SM. Human macrophages secrete platelet-activating factor acetylhydrolase. *J Biol Chem* 1990;265:9682-9687.
- 46 Tarbet EB, Stafforini DM, Elstad MR, Zimmerman GA, McIntyre TM, Prescott SM. Liver cells secrete the plasma form of platelet-activating factor acetylhydrolase. *J Biol Chem* 1991;266:16667-16673.
- 47 Tjoelker LW, Wilder C, Eberhardt C, Stafforini DM, Dietsch G, Schimpf B, et al. Anti-inflammatory properties of a platelet-activating factor acetylhydrolase. *Nature* 1995;374:549-553.
- 48 Zhang C, Hsueh W, Caplan MS, Kelly A. Platelet activating factor-induced shock and intestinal necrosis in the rat: role of endogenous platelet-activating factor and effect of saline infusion. *Crit Care Med* 1991;19:1067.
- 49 Siren AL, Feuerstein G. Effects of PAF and BN 52021 on cardiac function and regional blood flow in conscious rats. *Am J Physiol* 1989;257:H25-32.
- 50 Zhang C, Hsueh W. PAF-induced bowel necrosis. Effects of vasodilators. *Dig Dis Sci* 1991;36:634-640.
- 51 Hsueh W, Gonzalez-Crussi F, Arroyave JL. Release of leukotriene C4 by isolated, perfused rat small intestine in response to platelet-activating factor. *J Clin Invest* 1986;78: 108-114.
- 52 Hsueh W, Gonzalez-Crussi F, Arroyave JL. Sequential release of leukotrienes and norepinephrine in rat bowel after platelet-activating factor. A mechanistic study of platelet-

- activating factor-induced bowel necrosis. *Gastroenterology* 1988;94:1412-1418.
- 53 Sun X, Hsueh W. Platelet-activating factor produces shock, *in vivo* complement activation, and tissue injury in mice. *J Immunol* 1991;147:509-514.
- 54 Hsueh W, Sun X, Rioja LN, Gonzalez-Crussi F. The role of the complement system in shock and tissue injury induced by tumour necrosis factor and endotoxin. *Immunology* 1990;70:309-314.
- 55 Viscardi RM, Lyon NH, Sun CC, Hebel JR, Hasday JD. Inflammatory cytokine mRNAs in surgical specimens of necrotizing enterocolitis and normal newborn intestine. *Pediatr Pathol Lab Med* 1997;17:547-559.
- 56 Tan X, Sun X, Gonzalez-Crussi FX, Gonzalez-Crussi F, Hsueh W. PAF and TNF increase the precursor of NF-kappaB p50 mRNA in mouse intestine: Quantitative analysis by competitive PCR. *Biochim Biophys Acta* 1994;1215:157-162.
- 57 De Plaen IG, Tan XD, Chang H, Qu XW, Liu QP, Hsueh W. Intestinal NF-kB is activated, mainly as p50 homodimers, by platelet-activating factor. *Biochem Biophys Acta* 1998;1392:185-192.
- 58 De Plaen IG, Tan XD, Chang H, Liu Q, Remick DG, Hsueh W. Lipopolysaccharide activates nuclear factor kB in rat intestine: role of endogenous platelet-activating factor and tumor necrosis factor. *Br J Pharmacol* 2000;129:307-314.
- 59 De Plaen IG, Wang L, May MJ, Ghosh S, Qu XW, Hsueh W. Selective inhibition of nuclear factor-kB blocks the bowel injury induced by platelet-activating factor. *Pediatr Res* 2002; 51:809,139A.
- 60 Sun X, Qu XW, Huang W, Granger DN, Bree M, Hsueh W. The role of leukocyte beta 2-integrin in PAF-induced shock and intestinal injury. *Am J Physiol* 1996;270:G184-190.
- 61 Han XB, Liu X, Hsueh W, De Plaen IG. Macrophage inflammatory protein-2 mediates the bowel injury induced by platelet-activating factor. *Am J Physiol Gastrointest Liver Physiol* 2004;287:G1220-1226
- 62 Strieter RB, Kunkel SL, Bone RC. Role of tumor necrosis factors in disease states and inflammation. *Crit Care Med* 1993;21:S447-463.
- 63 Vilcek J, Lee TH. Tumor necrosis factor. New insights into the molecular mechanisms of its multiple actions. *J Biol Chem* 1991;266:7313-7316.
- 64 Beutler B. TNF, immunity and inflammatory disease: lessons of the past decade. *J Invest Med* 1995;43:227-275
- 65 Camussi G, Bussolino F, Salvidio G, Baglioni C. Tumor necrosis factor/cachectin stimulates peritoneal macrophages, polymorphonuclear neutrophils, and vascular endothelial cells to synthesize and release platelet-activating factor. *J Exp Med* 1987;166:1390-1404.
- 66 Fong YM, Marano MA, Moldawer LL, Wei H, Calvano SE, Kenney JS, et al. The acute splanchnic and peripheral tissue metabolic response to endotoxin in humans. *J Clin Invest* 1990;85:1896-1904.
- 67 Huang L, Tan X, Crawford SE, Hsueh W. Platelet-activating factor and endotoxin induce tumour necrosis factor gene expression in rat intestine and liver. *Immunology* 1994;83: 65-69.
- 68 Keshav S, Lawson L, Chung LP, Stein M, Perry VH, Gordon S. Tumor necrosis factor mRNA localized to Paneth cells of normal murine intestinal epithelium by *in situ* hybridization. *J Exp Med* 1990;171:327-332.
- 69 Tan XD, Hsueh W, Gonzalez-Crussi F. Cellular localization of TNF-alpha transcripts in normal bowel and in necrotizing enterocolitis. TNF gene expression in Paneth cells, intestinal eosinophils and macrophages. *Am J Pathol* 1993;142: 1858-1865.
- 70 Nevalainen TJ, Gronroos MJ, Kallajoki M. Expression of group II phospholipase A2 in the human gastrointestinal tract. *Lab Invest* 1995;72:201-208.
- 71 Tan XD, Wang H, Gonzalez-Crussi FX, Chang H, Gonzalez-Crussi F, Hsueh W. Platelet-activating factor and endotoxin increase the enzyme activity and gene expression of type II phospholipase A2 in the rat intestine. *J Immunol* 1996;156:2985-2990.
- 72 Collart MA, Baeuerle P, Vassalli P. Regulation of tumor necrosis factor alpha transcription in macrophages: Involvement of four kB-like motifs and of constitutive and inducible forms of NF-kB. *Mol Cell Biol* 1990;10:1489-1506.
- 73 Baeuerle PA. The inducible transcription activator NF-kB: regulation by distinct protein subunits. *Biochim Biophys Acta* 1991;1072:63-80.
- 74 Kubes P, Suzuki M, Granger DN. Platelet-activating factor-induced microvascular dysfunction: role of adherent leukocytes. *Am J Physiol* 1990;258:G158-163.
- 75 Kubes P, Arfors KE, Granger DN. Platelet-activating factor-induced mucosal dysfunction: role of oxidants and granulocytes. *Am J Physiol* 1991;260:G965-971.
- 76 Sun X, Rozenfeld RA, Qu XW, Huang W, Gonzalez-Crussi F, Hsueh W. P-selectin-deficient mice are protected from PAF-induced shock, intestinal injury, and lethality. *Am J Physiol* 1997;273:G56-61.
- 77 Tan XD, Chang H, Qu XW, Caplan M, Gonzalez-Crussi F, Hsueh W. PAF increases mucosal permeability in rat intestine via tyrosine phosphorylation of E-cadherin. *Br J Pharmacol* 2000;129:1522-1529.
- 78 Sun X, MacKendrick W, Tien J, Huang W, Caplan MS, Hsueh W. Endogenous bacterial toxin is required for the injurious effect of PAF. *Gastroenterology* 1995;109:83-88.
- 79 Sun X, Caplan MS, Liu Y, Hsueh W. Endotoxin resistant mice are protected from PAF-induced shock, tissue injury and death. Roles of TNF, complement activation and endogenous PAF production. *Dig Dis Sci* 1995;40:495-502.
- 80 Deitch EA, Ma L, Ma WJ, Grisham MB, Granger DN, Specian RD, et al. Inhibition of endotoxin-induced bacterial translocation in mice. *J Clin Invest* 1989;84:36-42.
- 81 Granger DN. Role of xanthine oxidase and granulocytes in ischemia-reperfusion injury. *Am J Physiol* 1988;255: H1269-1275.
- 82 Qu XW, Rozenfeld RA, Huang W, Bulkley GB, Hsueh W. The role of xanthine oxidase in platelet-activating factor induced intestinal injury in the rat. *Gut* 1999;44:203-211.
- 83 Kooij A, Bosch KS, Frederiks WM, Van Noorden CJ. High levels of xanthine oxidoreductase in rat endothelial, epithelial and connective tissue cells. A relation between localization and function? *Virchows Arch B Cell Pathol Incl Mol Pathol* 1992;62:143-150.
- 84 Cueva JP, Hsueh W. Role of oxygen derived free radicals in platelet activating factor induced bowel necrosis. *Gut* 1988;29:1207-1212.
- 85 Alderton WK, Cooper CE, Knowles RG. Nitric oxide synthases: structure, function and inhibition. *Biochem J* 2001; 357:593-615.
- 86 Qu XW, Wang H, Rozenfeld RA, Huang W, Hsueh W. Type

- I nitric oxide synthase (NOS) is the predominant NOS in rat small intestine: regulation by PAF. *Biochim Biophys Acta* 1999;1451:211-217.
- 87 Qu XW, Rozenfeld RA, Huang W, Sun XM, Tan XD, Hsueh W. Roles of nitric oxide synthases in platelet-activating factor-induced intestinal necrosis in rats. *Crit Care Med* 1999;27: 356-364.
  - 88 MacKendrick W, Caplan M, Hsueh W. Endogenous nitric oxide protects against platelet-activating factor-induced bowel injury in the rat. *Pediatr Res* 1993;34:222-228.
  - 89 Qu XW, Thaete LG, Rozenfeld R, Zhu Y, De Plaen IG, Caplan MS, et al. Tetrahydrobiopterin prevent platelet-activating factor-induced intestinal hypoperfusion and necrosis: role of neuronal nitric oxide synthase. *Crit Care Med* 2005;33: 1050-1056.
  - 90 Kubes P, McCafferty DM. Nitric oxide and intestinal inflammation. *Am J Med* 2000;109:150-158.
  - 91 Caplan M, Hedlund E, Hill N, MacKendrick W. The role of endogenous nitric oxide and platelet-activating factor in hypoxia-induced intestinal injury in rats. *Gastroenterology* 1994;106:346-352.
  - 92 MacKendrick W, Caplan M, Hsueh W. Endogenous nitric oxide protects against platelet-activating factor-induced bowel injury in the rat. *Pediatr Res* 1993;34:222-228.
  - 93 Moncada S, Higgs EA. The L-arginine-nitric oxide pathway. *N Engl J Med* 1993;329:2002-2012.
  - 94 Barlow B, Santulli TV, Heird WC, Pitt J, Blanc WA, Schullinger JN, et al. An experimental study of acute neonatal enterocolitis-the importance of breast milk. *J Pediatr Surg* 1974;9:587-594.
  - 95 Barlow B, Santulli TV. Importance of multiple episodes of hypoxia or cold stress on the development of enterocolitis in an animal model. *Surgery* 1975;77:687-690.
  - 96 Topalian SL, Ziegler MM. Necrotizing enterocolitis: a review of animal models. *J Surg Res* 1984;37:320-366.
  - 97 Caplan MS, Hedlund E, Adler L, Hsueh W. Role of asphyxia and feeding in a neonatal rat model of necrotizing enterocolitis. *Pediatr Pathol* 1994;14:1017-1028.
  - 98 Caplan MS, Hedlund E, Adler L, Lickerynan M, Hsueh W. The platelet-activating factor receptor antagonists WEB 2170 prevents neonatal necrotizing enterocolitis. *J Pediatr Gastroenterol Nutr* 1997;24:296-301.
  - 99 Caplan MS, Lickerman M, Adler L, Dietsch GN, Yu A. The role of recombinant platelet-activating factor acetylhydrolase in a neonatal rat model of necrotizing enterocolitis. *Pediatr Res* 1997;42:779-883
  - 100 Ewer AK, Al-Salti W, Coney AM, Marshall JM, Ramani P, Booth IW. The role of platelet activating factor in a neonatal piglet model of necrotizing enterocolitis. *Gut* 2004;53:207-213
  - 101 Caplan MS, Amer M, Jilling T. The role of human milk in necrotizing enterocolitis. *Adv Exp Med Biol* 2002;503: 83-90
  - 102 Caplan MS, Miller-Catchpole R, Kaup S, Russell T, Lickerman M, Amer M, et al. Bifidobacterial supplementation reduces the incidence of necrotizing enterocolitis in a neonatal rat model. *Gastroenterol* 1999;117:577-583.
  - 103 Lin HC, Su BH, Chen AC, Lin TW, Tsai CH, Yeh TF, et al. Oral probiotics reduce the incidence and severity of necrotizing enterocolitis in very low birth weight infants. *Pediatrics* 2005;115:1-4.
  - 104 Bin-Nun A, Bromiker R, Wilschanski M, Kaplan M, Rudensky B, Caplan M, et al. Oral probiotics prevent necrotizing enterocolitis in very low birth weight neonates. *J Pediatr* 2005;147:192-196
  - 105 Ezendam J, van Loveren LH. Probiotics: immunomodulation and evaluation of safety and efficacy. *Nutr Rev* 2006;64:1-14
  - 106 Land MH, Rouster-Stevens K, Woods CR, Cannon ML, Cnota J, Shetty AK. Lactobacillus sepsis associated with probiotic therapy. *Pediatrics* 2005;115:178-181.
  - 107 Kamada N, Inoue N, Hisamatsu T, Okamoto S, Matsuoka K, Sato T, et al. Nonpathogenic Escherichia coli strain Nissle1917 prevents murine acute and chronic colitis. *Inflamm Bowel Dis* 2005;11:455-463.
  - 108 Caplan MS, Sun XM, Hsueh W, Hageman JR. Role of platelet activating factor and tumor necrosis factor-alpha in neonatal necrotizing enterocolitis. *J Pediatr* 1990;116: 960-964.
  - 109 Rabinowitz SS, Dzakpasu P, Piecuch S, Leblanc P, Valencia G, Kordecki E. Platelet-activating factor in infants at risk for necrotizing enterocolitis. *J Pediatr* 2001;138:81-86.
  - 110 MacKendrick W, Hill N, Hsueh W, Caplan M. Increase in plasma platelet-activating factor levels in enterally fed preterm infants. *Biol Neonate* 1993;64:89-95.
  - 111 Amer MD, Caplan MS. Neonatal necrotizing enterocolitis increases platelet activating factor levels in the stool of newborn infants. *Clin Res* 1994;42:372A.
  - 112 Farr RS, Wardlow ML, Cox CP, Meng KE, Greene DE. Human serum acid-labile factor is an acylhydrolase that inactivates platelet-activating factor. *Federation Proc* 1983; 42:3120-3122.
  - 113 Caplan M, Hsueh W, Kelly A, Donovan M. Serum PAF acetylhydrolase increases during neonatal maturation. *Prostaglandins* 1990;39:705-714.
  - 114 Lucas A, Cole TJ. Breast milk and neonatal necrotizing enterocolitis. *Lancet* 1990;336:1519-1523.
  - 115 Furukawa M, Lee EL, Johnston JM. Platelet-activating factor-induced ischemic bowel necrosis: the effect of platelet-activating factor acetylhydrolase. *Pediatr Res* 1993; 34:237-241.

Received April 29, 2006

Accepted after revision August 26, 2006