

Primary hyperoxaluria in a compound heterozygote infant

Juan Mayordomo-Colunga, Debora Riverol, Eduardo Salido, Fernando Santos

Oviedo and Tenerife, Spain

Background: Primary hyperoxaluria type 1 is a rare disorder caused by a defect in the hepatic metabolism of glyoxylate. Cases presenting in infancy are very uncommon and often have a severe course leading to early end-stage renal failure.

Methods: We treated a case of early presentation of primary hyperoxaluria type 1 and reviewed the relevant literature.

Results: A 4-month-old female infant was admitted to our hospital because of acute renal failure and nephrocalcinosis. Mutational analysis of alanine-glyoxylate aminotransferase gene revealed compound heterozygosity in the infant, confirming the development of primary hyperoxaluria type 1. A few weeks later, the condition of the infant worsened during an interdialytic period and died.

Conclusions: Interest of this case is based on the coexistence of two mutations of alanine-glyoxylate aminotransferase gene recently reported, and it confirms the severe course of the disease when it presents in infancy. It also highlights the importance of the association of nephrocalcinosis and urolithiasis as key diagnostic manifestations of primary hyperoxaluria type 1.

World J Pediatr 2011;7(2):173-175

Key words: calcium oxalate;
nephrocalcinosis;
primary hyperoxaluria;
renal failure

Author Affiliations: Pediatric Nephrology, Department of Pediatrics, Hospital Universitario Central de Asturias & University of Oviedo, Oviedo, Spain (Mayordomo-Colunga J, Santos F); Research Unit, Hospital Universitario Canarias & University La Laguna, Tenerife, Spain (Riverol D, Salido E)

Corresponding Author: Juan Mayordomo-Colunga, MD, Servicio de Pediatría, Hospital Universitario Central de Asturias, Celestino Villamil, s/n. 33006 Oviedo, Spain (Tel: +34 636717615; Fax: +34 985107853; Email: jmcolunga@hotmail.com)

doi: 10.1007/s12519-010-0214-z

©Children's Hospital, Zhejiang University School of Medicine, China and Springer-Verlag Berlin Heidelberg 2010. All rights reserved.

Introduction

Primary hyperoxaluria type 1 (PH1) is a rare disorder caused by a defect in the hepatic metabolism of glyoxylate. Glyoxylate is not converted into glycine but to oxalate through alternative metabolic pathways. Oxalate overproduction causes calcium oxalate depositions, which produce renal and systemic damage.^[1] PH1 is an autosomal recessive disease caused by loss-of-function mutations in the gene encoding alanine-glyoxylate aminotransferase (AGXT; 604285) on 2q36-q37.^[2]

Case report

A 4-month-old female infant, with no significant past medical history, was admitted to our hospital because of acute renal failure (plasma creatinine and blood urea nitrogen (BUN) levels 3.44 and 175 mg/dl, respectively). The only remarkable family history was that her mother had had a nephritic colic and a maternal uncle had died of an unknown renal disease. The parents denied consanguinity and had 2 other healthy sons.

At admission, the child appeared critically ill, with generalized edema, palpable hepatomegaly, pallor and tachypnea (42 breaths per minute) and intermittent groaning. Blood pressure was 108/42 mmHg. Renal ultrasonography revealed nephrocalcinosis and urolithiasis. With the suspicion of PH1, oxalate plasma level (16.1 $\mu\text{mol/L}$, 95th percentile for infants 5.58 $\mu\text{mol/L}$),^[3] and urinary excretion of oxalate (542 mmol/mol creatinine; normal reference values up to 54 mmol/mol creatinine) were determined. Electrolytes and water were replaced and the infant was treated intravenously with bicarbonate, pyridoxine, sodium citrate and thiazides. Chronic hemodialysis and peritoneal dialysis were started. A few weeks later and while waiting for a liver and kidney transplantation, the condition of the infant worsened during an interdialytic period and the infant died.

Mutational analysis of the AGXT gene showed heterozygosity in the parents, c.847-3C>G in the father and c.33dupC in the mother, and compound heterozygosity in the infant for both mutations (Fig. 1). Both siblings of the infant showed no mutational anomalies.

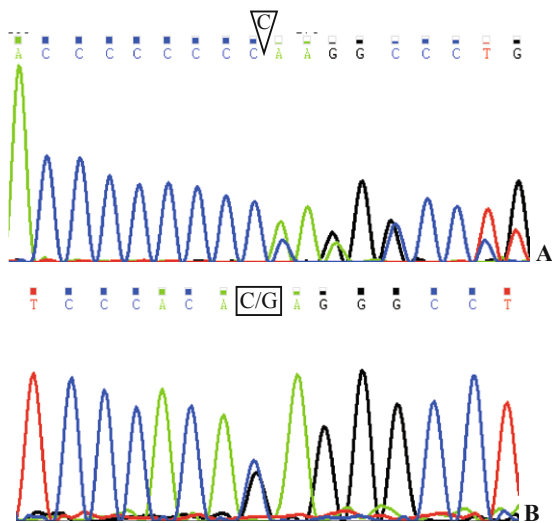


Fig. 1. Mutational analysis showing compound heterozygosity. **A:** c.33dupC mutation; **B:** c.847-3C>G mutation.

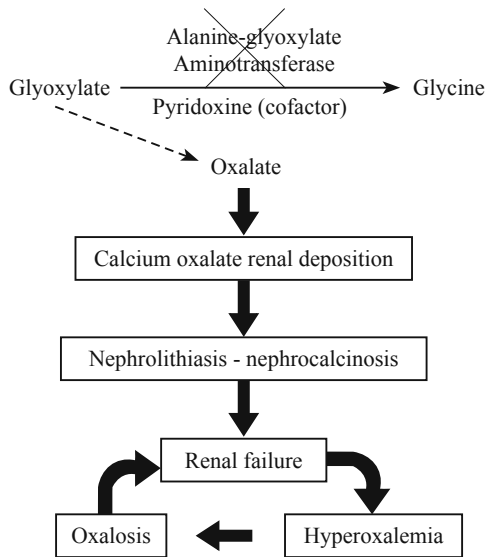


Fig. 2. Pathophysiology of primary hyperoxaluria type 1.

Discussion

Mutation of the AGXT gene results in a partial or complete deficiency of enzyme alanine-glyoxylate aminotransferase (AGT) or a misplacement of the enzyme out of its normal intracellular location in the peroxisome.^[4] The lack of enzymatic function causes oxalate elevation in blood and formation of calcium compounds with a very low solubility. Deposition of these compounds in the kidneys and urinary tract leads to nephrocalcinosis, urolithiasis and produces progressive and irreversible renal damage. Subsequent deposition of these compounds in other organism tissues gives rise to the full clinical and biochemical spectrum of oxalosis.^[5] Fig. 2 summarizes the pathophysiology of PH1.

So far, a total of 146 mutations have been described on the AGXT gene.^[6] The two found in our patient were c.33dupC^[7] (formerly c.33_34insC) and c.847-3C>G^[8]. The first one is quite common in PH1 patients, and when present in homozygosis, AGT activity is very low. The onset of the disease occurs in the early years of life in these cases.^[6] The latter mutation is one of the 18 found at the intron-exon boundary. To our knowledge, it has only been reported in 2 cases.^[8]

As an inborn error, AGT dysfunction is present at birth, but clinical manifestations may appear from infancy to adulthood because of the great heterogeneity of the disease. Even siblings with identical mutation may manifest a completely different phenotype.^[9] Presenting manifestations of PH1 are urological symptoms such as lumbar pain, hematuria, recurrent urinary tract infections and calculus in 80% of cases.^[5] Less than 10% PH1 patients develop symptoms during infancy.^[10] These forms of early debut are severe and rapidly lead to end-stage renal failure. In contrast, other patients with symptoms in the early years of life do not progress to renal failure until adulthood.

Nowadays, the only curative treatment of PH1 is liver-kidney transplantation^[11] or just liver transplantation in those patients without clinical renal damage.^[12] Promising results following liver repopulation with normal hepatocytes have been recently reported in an animal model.^[13] Until transplantation is performed, intensive dialysis using combined peritoneal dialysis and hemodialysis is essential to reduce oxalemia and tissue deposition of oxalate compounds. Medical treatment with crystallization inhibitors (phosphate salts, magnesium and sodium citrate), thiazides and fluids replenishment as well as suppression of food rich in oxalate (strawberry, chocolate, coffee, tea) and vitamin C are also recommended. A trial with pyridoxine, the cofactor of AGT enzyme for 3 to 6 months may lead to significant reduction in oxalate excretion in a small proportion of patients.^[5]

The case we treated shows the coexistence of two mutations of the AGXT gene recently reported,^[7,8] serves to remind the importance of the association of nephrocalcinosis and urolithiasis as key diagnostic manifestations of PH1 and confirms the severe course of the disease when it presents in infancy.

Funding: This study was partly supported by grant SAF2007-62343 from the "Ministerio de Ciencia".

Ethical approval: The parents of the infant provided informed consent to the diagnostic and therapeutic procedures involved, in agreement with the guidelines approved by our institutional clinical research ethics committee.

Competing interest: The authors declare that they have no financial

relationships to disclose.

Contributors: Mayordomo-Colunga J and Santos F wrote the manuscript and were the responsible physicians of the patient. Riverol D and Salido E performed the mutational analysis and reviewed and approved the manuscript.

References

- 1 Danpure CJ, Jennings PR. Peroxisomal alanine: glyoxylate aminotransferase deficiency in primary hyperoxaluria type I. *FEBS Lett* 1986;201:20-24.
- 2 Purdue PE, Lumb MJ, Fox M, Griffo G, Hamon-Benais C, Povey S, et al. Characterization and chromosomal mapping of a genomic clone encoding human alanine:glyoxylate aminotransferase. *Genomics* 1991;10:34-42.
- 3 Porowski T, Zoch-Zwierz W, Konstantynowicz J, Korzeniecka-Kozerska A, Michaluk-Skutnik J, Porowska H. Reference values of plasma oxalate in children and adolescents. *Pediatr Nephrol* 2008;23:1787-1794.
- 4 Danpure CJ. The molecular basis of alanine: glyoxylate aminotransferase mistargeting: the most common single cause of primary hyperoxaluria type I. *J Nephrol* 1998;11 Suppl 1:8-12.
- 5 Cochat P. Primary hyperoxaluria type I. *Kidney Int* 1999;55:2533-2547.
- 6 Williams EL, Acquaviva C, Amoroso A, Chevalier F, Coulter-Mackie M, Monico CG, et al. Primary hyperoxaluria type 1: update and additional mutation analysis of the AGXT gene. *Hum Mutat* 2009;30:910-917.
- 7 Pirulli D, Puzzer D, Ferri L, Crovella S, Amoroso A, Ferretini C, et al. Molecular analysis of hyperoxaluria type I in Italian patients reveals eight new mutations in the alanine: glyoxylate aminotransferase gene. *Hum Genet* 1999;104:523-525.
- 8 Basmaison O, Rolland MO, Cochat P, Bozon D. Identification of 5 novel mutations in the AGXT gene. *Hum Mutat* 2000;15:577.
- 9 Hoppe B, Danpure CJ, Rumsby G, Fryer P, Jennings PR, Blau N, et al. A vertical (pseudodominant) pattern of inheritance in the autosomal recessive disease primary hyperoxaluria type I. Lack of relationship between genotype, enzymic phenotype and disease severity. *Am J Kidney Dis* 1997;29:36-44.
- 10 Kamoun A, Ben Moussa F, Ben Maiz H, Lakhoua R. Infantile forms of primary hyperoxaluria type I: apropos of 4 cases. *Arch Pediatr* 1996;3:997-1000.
- 11 Jamieson NV. A 20-year experience of combined liver/kidney transplantation for primary hyperoxaluria (PH1): the European PH1 transplant registry experience 1984-2004. *Am J Nephrol* 2005;25:282-289.
- 12 Shapiro R, Weismann I, Mandel H, Eisenstein B, Ben-Ari Z, Bar-Nathan N, et al. Primary hyperoxaluria type 1: improved outcome with timely liver transplantation: a single-center report of 36 children. *Transplantation* 2001;72:428-432.
- 13 Jiang J, Salido EC, Guha C, Wang X, Moitra R, Liu L, et al. Correction of hyperoxaluria by liver repopulation with hepatocytes in a mouse model of primary hyperoxaluria type-1. *Transplantation* 2008;85:1253-1260.

Received April 20, 2009

Accepted after revision August 28, 2009