

# Glial fibrillary acidic protein expression is an indicator of teratoma maturation in children

Song Gu, Ye-Ming Wu, Li Hong, Zhong-De Zhang, Min-Zhi Yin  
Shanghai, China

**Background:** The present diagnosis of teratomas is limited to visual examination of their tissues. For the sake of treatment, teratomas are graded according to degrees of nerve tissue maturation. Mature fetal nerve tissue contains the astrocyte-specific intermediate filament protein, the glial fibrillary acidic protein (GFAP). This study aimed to investigate GFAP expressions in the nerve tissue of immature and mature teratomas, and to evaluate if GFAP is indicative of teratoma maturation in pediatric patients.

**Methods:** Nerve tissue specimens were collected from immature (10 children) and mature teratomas (45 children). Nerve tissue specimens as a control group were taken from 33 children with neuroblastoma. GFAP expression of the specimens was studied by immunohistochemical and semi-quantitative analyses.

**Results:** GFAP expression was low in the nerve tissue of immature teratomas and high in that of mature ones. A semi-quantitative analysis confirmed statistically significant difference between the GFAP expressions of immature and mature teratomas ( $P=0.0001$ ).

**Conclusion:** GFAP is highly expressed in the nerve tissue of mature teratomas and low in that of immature ones, suggesting that the GFAP expression is a meaningful indicator of teratoma maturation. It is helpful for pathologists to diagnose and classify teratomas.

*World J Pediatr 2011;7(3):262-265*

**Key words:** children;  
glial fibrillary acidic protein;  
nerve tissue;  
teratoma

**Author Affiliations:** Department of Pediatric Surgery (Gu S, Hong L) and Department of Pathology (Zhang ZD, Yin MZ), Shanghai Children's Medical Center, School of Medicine, Shanghai Jiaotong University, Shanghai 200127, China; Department of Pediatric Surgery, Xinhua Hospital, School of Medicine, Shanghai Jiaotong University, Shanghai 200092, China (Wu YM)

**Corresponding Author:** Ye-Ming Wu, Department of Pediatric Surgery, Xinhua Hospital, Shanghai 200092, China (Tel: +86-21-65790000-3008, Fax: +86-21-65795173; Email: wuyeming57@hotmail.com)

doi:10.1007/s12519-011-0258-8

©Children's Hospital, Zhejiang University School of Medicine, China and Springer-Verlag Berlin Heidelberg 2011. All rights reserved.

## Introduction

Teratomas are neoplasms composed of tissue elements foreign to the organ or anatomic site of origin. In children, these tumors are notable for their diverse anatomic locations and biological characteristics. To date, the pathological diagnosis of teratomas has been limited to the presence of tissue or organ components resembling normal derivatives of all three germ layers. The classification system of teratomas that is currently in use and based on the degree of maturation of the nerve tissue in teratomas has proven to be greatly relevant to the clinical outcome for pediatric patients.<sup>[1-3]</sup>

Mature nerve tissue in fetuses contains an astrocyte-specific intermediate filament (IF) protein, the glial fibrillary acidic protein (GFAP).<sup>[4]</sup> Thus the present study was undertaken to investigate whether and to what extent GFAP is expressed in the nerve tissue of immature or mature teratomas and to evaluate whether the GFAP expression can be an indicator of teratoma maturation in pediatric patients.

## Methods

Nerve tissue specimens of teratomas were collected from 55 children who had been diagnosed pathologically at the Shanghai Xinhua Hospital and the Shanghai Children's Medical Center, including 10 immature and 45 mature teratomas. The children aged from 2 days to 12.5 years had received either primary or secondary resection for teratomas. The tumors were located at the sacrococcygeal area (23 children), peritoneal area (18), ovary (7), testicle (7), and mediastinal area (5). They had been treated between January 2000 and December 2006. GFAP expression was compared in the nerve tissue specimens by immunohistochemical and semi-quantitative methods.

Because neuroblastomas with immature nerve tissue types are occasionally seen in immature teratomas, nerve tissue specimens of neuroblastomas from 33 children who had been treated at the Xinhua Hospital and Shanghai Children's Medical Center served as a control group.

### Tissue microarray (TMA)<sup>[5]</sup>

Briefly, the hematoxylin-eosin (HE) slides for the initial diagnosis were re-examined by an experienced pathologist. Two morphologically representative fields of nerve tissue were chosen and encircled with a marker pen. Subsequently, two cores from each case were punched out from the donor blocks. Starting from the selected regions, the corresponding HE slides were overlaid with a custom-built Becton-Dickinson Precision Glide<sup>®</sup> hypodermic needle (2 mm in diameter). The cores were then attached by double-sided adhesive tape to a computer-generated paper grid facilitating alignment on the block mould, which was filled with liquid paraffin. 4 µm thick sections were obtained using an American optical standard rotator microtome. Each block provided 40-50 slides, which were stored in sections at 58°C overnight. Only samples showing the original lesion were considered. The design of each block was detailed in a TMA map (spreadsheet), indicating the position and identification of each core. Normal tissue (placenta) and position-specific blank cores were adopted for orientation during microscopic analysis.

### Immunohistochemical (IHC) analysis

IHC reactions were performed on TMA silane-coated slides (Sigma, St. Louis, MO, USA), dried overnight at 37°C and then dewaxed, rehydrated and treated in 3% hydrogen peroxide for 10 minutes to eliminate endogenous peroxidase activity. For immunolabeling, we used an LSAB kit with HRP (Dakocytomation, Carpinteria, CA, USA) in accordance with the manufacturer's instructions. Tissue sections were incubated sequentially for 1 hour at room temperature with the specific antibodies (1/1000) of mouse anti-GFAP monoclonal antibody, clone GF-01 (1/50) (Abcam, USA) to stain cytoplasm. A secondary biotinylated multilink antibody was incubated for 30 minutes using a streptavidin-HRP conjugate, and the signal was visualized with 3.3 diaminobenzidine (Sigma Chemical Co., St. Louis, MO, USA) and 85 µL of 0.3% hydrogen peroxide. Hematoxylin was used for counterstaining. The omission of the primary antibody, which eliminated the signal in each case, served as an additional control.

### Assessment of IHC slides and cell counting

The slides were analyzed microscopically by two independent investigators. Cells showing a positive staining of cytoplasm which were clear and free from any background color were counted. The following counting criteria were applied: positive cells <5% as (-), positive cells ≥5% but <25% as (+), positive cells ≥25% but <50% as (++) , positive cells ≥50% but <75%

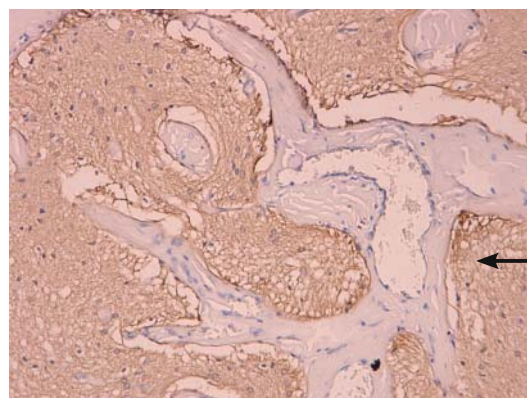
as (+++), positive cells ≥75% as (++++).

### Statistical analysis

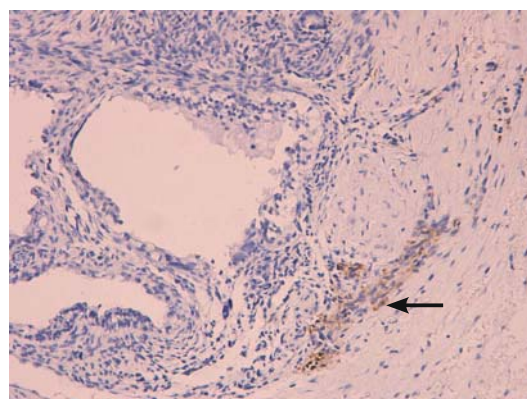
Data analysis was made using an SAS system (SAS version 6.1, Cary, North Carolina, USA). Non-parametric tests were performed for comparison. The Wilcoxon rank sum test was used to compare the mean of cells of the positive cytoplasm staining between immature and mature teratomas.  $P < 0.05$  was considered statistically significant.

### Results

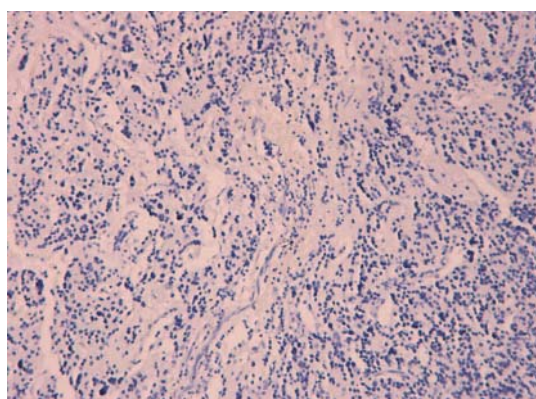
A low level of GFAP expression was found in immature teratomas ( $n=10$ ), 0 to + (an average of 0.6+), and a significantly higher expression in mature teratomas ( $n=45$ ), 2+ to 4+ (an average of 2.58+). The comparison between the two groups demonstrated a significant difference ( $P=0.0001$ ) (Figs. 1 and 2). In the control group, the GFAP expression was negative (Fig. 3).



**Fig. 1.** The expression of glial fibrillary acidic protein in a mature teratoma shown by immunohistochemical staining (++++). The positive cells were stained brown (arrow, cytoplasm) (original magnification × 400).



**Fig. 2.** The expression of glial fibrillary acidic protein in an immature teratoma. The positive cells were stained brown (arrow, cytoplasm) with a degree of + (original magnification × 400).



**Fig. 3.** Immunohistochemical analysis: negative expression of the glial fibrillary acidic protein in the control group (original magnification  $\times 400$ ).

## Discussion

Immature teratoma is defined as a tumor containing immature embryo components, usually immature primitive neuroectodermal tissue.<sup>[1,3]</sup> Based on the number of immature components, immature teratomas are graded I-III. Thus immature nerve tissue plays a significant role in this grading system. Pathologists often consider grade I immature teratoma a tumor that lies in between benign and malignant. A grade II immature teratoma, on the other hand, is considered a malignant tumor in adults, and a grade III immature teratoma as a high-stage cancer.<sup>[6]</sup>

In children, however, the clinical and biological characteristics of immature teratoma have not yet been clearly clarified, and there are controversies over the treatment of the tumor. Traditionally, immature teratoma in children is considered an advanced carcinoma,<sup>[7]</sup> but some researchers consider all immature teratomas in children as benign because even grade III immature teratomas have a good prognosis after a complete resection.<sup>[8]</sup> In our practice, children who had immature teratomas completely resected were not subjected to chemotherapy in order to reduce side effects.

A study on Chinese adult patients with immature teratomas who were not subjected to chemotherapy reported that the survival rates of grade I-III patients were 82%, 63% and 30% respectively,<sup>[9]</sup> suggesting that chemotherapy for adult patients depends on the severity of the tumor. However, a study by the Children's Cancer Study Group from UK reported that simple surgery is suitable for any grade of immature teratoma, and that only the relapse cases need chemotherapy.<sup>[10]</sup>

The treatment and prognosis of immature teratomas are still controversial.<sup>[11]</sup> It is necessary to find a new diagnostic method, such as a new IHC marker. Thus the new diagnostic method for investigating and measuring GFAP expression proposed in this study is to unify the

diagnosis and treatment of teratomas.

It has already been shown that the nervous tissue of mature and immature teratomas plays an important role in the diagnosis and classification of teratomas. Since GFAP has been found to be a constituent of fetal neuroectodermal tissue, we examined and compared the GFAP expression in nerve tissue specimens taken from pediatric patients by immunohistochemical and semi-quantitative analyses to find a potential basis for classification of mature and immature teratomas. GFAP is an intermediate filament protein and an astrocytoma-specific protein that expresses with the development of astrocytes in the fetal nerve tissue. GFAP is considered the best specific tumor marker of astrocytoma and astrocytic tumors. A strong expression of GFAP often suggests that tumor cells are mature, and well differentiated, indicating a more precise prognosis.<sup>[12]</sup>

In the present study, the GFAP expression was low in the nerve tissue of immature teratomas, and high in mature teratomas. This finding suggests that there are normal, well-differentiated astrocytes in the nerve tissue of the mature teratomas.<sup>[13]</sup> It also suggests that immature nerve tissue exists in immature teratomas. Therefore, nerve tissue is one of the main factors affecting the prognosis of immature teratomas. When the recurrence of teratomas was caused by seeding or metastasis with a very low expression of GFAP, the specimens obtained by re-operation were still found with negative staining of GFAP in the neural tissue, which was confirmed in this study. The nerve tissue in immature teratoma is made up of the original neural tube and its surrounding immature nerve tissue. Its immaturity was increasingly demonstrated in the process of improving the classification system (grades I-III).<sup>[14]</sup> Our study confirmed that there was a high expression of GFAP in the mature nerve tissue of mature teratomas, and a low or negative GFAP staining in the immature nerve tissue of immature teratomas. The GFAP expression in the control group was negative, suggesting that the nerve tissue of neuroblastoma was far from mature, and was potentially able to differentiate into mature neural epithelial cells.

In conclusion, our results suggest that GFAP is an indicator gauging the maturation of teratomas. Since the expression of GFAP can be determined by laboratory analysis, the GFAP expression is helpful for pathologists to diagnose and classify teratomas. In other words, the high expression level of GFAP indicates mature teratomas that require only a complete resection, whereas teratomas with the negative expression of GFAP might require additional chemotherapy to reduce the seeding, metastasis or recurrence of the tumor.

**Funding:** This study was supported by a grant from the National Natural Science Foundation of China (No. 30600751).

**Ethical approval:** Not needed.

**Competing interest:** No benefits in any form have been received or will be received from a commercial party related directly or indirectly to the subject of this article.

**Contributors:** Gu S wrote the main body of the article under the supervision of Wu YM. Hong L, Zhang ZD and Yin MZ provided advice on medical aspects. Wu YM is the guarantor.

## References

- Harms D, Zahn S, Göbel U, Schneider DT. Pathology and molecular biology of teratomas in childhood and adolescence. *Klin Padiatr* 2006;218:296-302.
- Gonzalez-Crussi F. Extragonadal teratoma. Atlas of tumor pathology, 2nd series, fascicle 18. Washington, DC: Armed Forces Institute of Pathology, 1982.
- Heifetz SA, Cushing B, Giller R, Shuster JJ, Stolar CJ, Vinocur CD, et al. Immature teratomas in children: pathologic considerations: a report from the combined Pediatric Oncology Group/Children's Cancer Group. *Am J Surg Pathol* 1998;22:1115-1124.
- Notohara K, Hsueh CL, Awai M. Glial fibrillary acidic protein immunoreactivity of chondrocytes in immature and mature teratomas. *Acta Pathol Jpn* 1990;40:335-342.
- Simon R, Mirlacher M, Sauter G. Tissue microarrays. *Biotechniques* 2004;36:98-105.
- Culine S, Lhomme C, Kattan J, Michel G, Duvillard P, Droz JP. Pure malignant immature teratoma of the ovary: the role of chemotherapy and second-look surgery. *Int J Gynecol Cancer* 1995;5:432-437.
- Göbel U, Calaminus G, Schneider DT, Koch S, Teske C, Harms D. The malignant potential of teratomas in infancy and childhood: the MAKEI experiences in non-testicular teratoma and implications for a new protocol. *Klin Padiatr* 2006;218:309-314.
- Cushing B, Giller R, Ablin A, Cohen L, Cullen J, Hawkins E, et al. Surgical resection alone is effective treatment for ovarian immature teratoma in children and adolescents: a report of the pediatric oncology group and the children's cancer group. *Am J Obstet Gynecol* 1999;181:353-358.
- Fan Q, Huang H, Lian L, Lang J. Characteristics, diagnosis and treatment of hepatic metastasis of pure immature ovarian teratoma. *Chin Med J* 2001;114:506-509.
- Mann JR, Gray ES, Thornton C, Raafat F, Robinson K, Collins GS, et al. Mature and immature extracranial teratomas in children: the UK Children's Cancer Study Group Experience. *J Clin Oncol* 2008;26:3590-3597.
- Kim E, Bae TS, Kwon Y, Kim TH, Chung KW, Kim SW, et al. Primary malignant teratoma with a primitive neuroectodermal tumor component in thyroid gland: a case report. *J Korean Med Sci* 2007;22:568-571.
- Rutka JT, Smith SL. Transfection of human astrocytoma cells with glial fibrillary acidic protein complementary DNA: analysis of expression, proliferation and tumorigenicity. *Cancer Res* 1993;53:3624-3631.
- Malhotra S, Shnitkn T, Elabrink J. Reactive astrocytes. A review. *Cytobios* 1990;61:133-160.
- Kang MK, Ahn YC, Park JO, Han J, Lee KS. Lung metastasis from an immature teratoma of the nasal cavity masquerading as small cell carcinoma of the lung. *Yonsei Med J* 2006;47:571-574.

Received March 9, 2010

Accepted after revision May 10, 2010