

Successful rescue of a child with fall-related multi-organ injuries

Zi-Hao Yang, Chen-Mei Zhang, Xiao-Fang Lou, Zhen-Jie Chen, Sheng Ye

Hangzhou, China

Background: Fall-related injury is a major cause of accidental death and is rarely reported in children. Even successful treatment of children with multi-organ injuries caused by fall from the extreme height has been rarely reported.

Methods: We herein report a 2-year-old girl who fell from the 10th floor, had multi-organ injuries, and was successfully rescued.

Results: The girl sustained multi-organ injuries, such as head injury, closed abdominal injury, as well as fractures of the left limbs, and successfully recovered after two surgeries and supportive treatment.

Conclusions: This case illustrates that a child who falls from extreme heights can occasionally be rescued. Early neuroprotective strategies help to improve neurological recovery.

World J Pediatr 2013;9(3):281-283

Key words: child;
fall-related injury;
trauma

Introduction

Falls are the most common cause of fatal injuries in the home environment.^[1] Vertical deceleration injuries represent a significant cause of preventable deaths and long-term morbidity in survivors.^[2] Reports of successful rescue of multi-organ injuries after a fall from considerable heights are rare. We herein report a 2-year-

old girl who fell from the 10th floor of a building in Hangzhou City of China. The fall was slowed by a neighbor, who tried to catch the child. Although the child sustained multi-organ injuries, she successfully recovered after 21 days of therapy.

Case report

A 2-year-old girl was hospitalized because of fall-related injuries. Three hours before admission, she fell from the 10th floor and dropped onto the roadside grass after blockage by a neighbor's forearms. The child was alert at that time and subsequently developed frequent vomiting and hematemesis. Ten minutes later, an ambulance took the child to a local hospital. Emergency physicians placed a cervical collar and sent her to the emergency department of our hospital.

After admission, the temperature (T), heart rate (HR), respiratory rate (RR), and blood pressure (BP) were 39.4°C, 188 beats/min, 38 breaths/min, and 106/61 mmHg, respectively. Her score on the Glasgow Coma Scale (GCS) was 9. Her consciousness was drowsy, and she had pale skin and contusions on the face and back. The right-side lung sounds were slightly lower than the left-side lung sounds. No abnormal heart sounds were detected on auscultation. She had a distended abdomen, abdominal muscle tension, upper abdominal tenderness, rebound pain, shifting dullness, and weak gurgling sounds. Chest X-ray and abdominal computed tomography (CT) showed free abdominal air (Figs. 1 and 2). Cranial CT showed no obvious bleeding.

Two hours after admission, emergency exploratory laparotomy was performed to repair the gastric perforation, liver laceration, and splenic rupture, while peritoneal lavage and drainage were carried out. Ventilatory support was continued, and mild cerebral hypothermia was provided postoperatively. Mannitol was administered to reduce the intracranial pressure. Meropenem and vancomycin were administered to prevent infection, and hemostatic resuscitation was performed for supportive treatment. Twelve hours after admission, complete blood count (CBC) showed a white blood cell (WBC) level of $18.1 \times 10^3/\mu\text{L}$, a neutrophil (N) level of 85.6%, and a C-reactive protein

Author Affiliations: Department of Pediatric ICU, Children's Hospital of Zhejiang University School of Medicine and Zhejiang Laboratory for Diagnosis and Therapy of Neonatal Disease, Hangzhou 310003, China (Yang ZH, Zhang CM, Lou XF, Chen ZJ, Ye S)

Corresponding Author: Sheng Ye, Department of Pediatric ICU, Children's Hospital of Zhejiang University School of Medicine, 57 Zhugan Xiang, Hangzhou 310003, China (Tel: +86-13588074637; Fax: +86-571-87033296; Email: yeshengchina@126.com)

doi: 10.1007/s12519-013-0401-9

©Children's Hospital, Zhejiang University School of Medicine, China and Springer-Verlag Berlin Heidelberg 2013. All rights reserved.

(CRP) level of >160 mg/L. Radiographic images of the bones and chest revealed fractures in the left proximal and distal radius as well as fractures of the distal fibula and tibia, pulmonary contusion, and a large area of right pneumothorax (Figs. 3 and 4). A chest tube was then placed. Craniospinal magnetic resonance imaging (MRI) revealed multiple abnormal patchy signals within the white matter of both cerebral hemispheres and cervical spinal cord contusion (Fig. 5). Abdominal ultrasound revealed non-uniform liver echogenicity and a small amount of fluid under the capsules of the liver and spleen. Metronidazole and methylprednisolone were administered to treat possible intra-abdominal anaerobic infections and possible spinal cord injury, respectively. During this treatment, the child's GCS score decreased to 3, BP decreased to 68/34 mmHg, and a high blood sugar (BS) level of 15.8 mmol/L was measured. Fluid resuscitation was performed, and vasoactive drugs including epinephrine and dopamine

were intravenously administered to elevate the BP. Insulin was administered intravenously to treat the hyperglycemia. Five days after admission, the child improved with a GCS score of 9, T of 36.2°C , BP of 103/65 mmHg, HR of 110 beats/min, capillary refill time of 2 seconds, and BS of 8.8 mmol/L. Extubation was then performed, and the chest tube was removed.

Ten days after admission, the child became alert, but developed another high fever. The CBC showed a high WBC level of $22.8 \times 10^3 / \mu\text{L}$, a N level of 83.2%, and a CRP level of 146 mg/L. Chest and abdominal CT revealed left pleural effusion and a dark area of perisplenic fluid. A second surgery was performed that night to remove the perisplenic abscess, and 200 mL of pus was drained via abdominal drainage. The same antibiotics were continued together with fluid support and symptomatic treatment after the second surgery. The CBC, CRP level, and liver function returned to normal levels on day 13 after admission. In addition, the patient responded well to enteral nutrition, which was provided the next day. However, she had flaccid hemiparesis in the left upper and lower extremities, low myodynamia (grade 0), and binocular vision loss. Cranial and spinal MRI re-examinations revealed improved intracranial and cervical spinal cord lesions. Twenty-three days after admission, additional oxygen requirements were discontinued. Her vision recovered slightly, and she could identify objects at a close range. The myodynamia of the left limbs recovered to grade 3, and the peritoneal cavity drainage tube

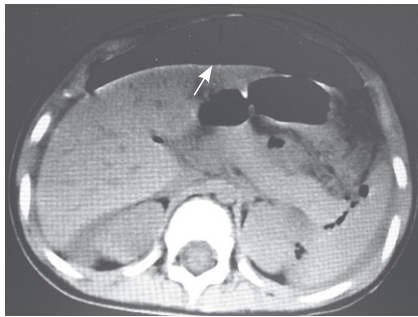


Fig. 1. CT scan showing a massive gas shadow in the abdomen.

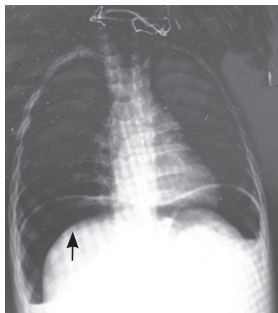


Fig. 2. Abdominal X-ray showing bilateral subphrenic free gas.

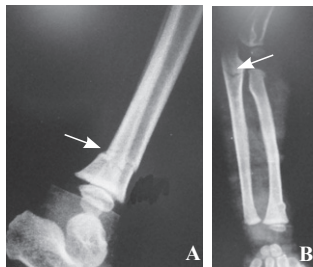


Fig. 3. Left limb bone X-ray showing fractures in the left proximal and distal radius (A) and the distal fibula and tibia (B).

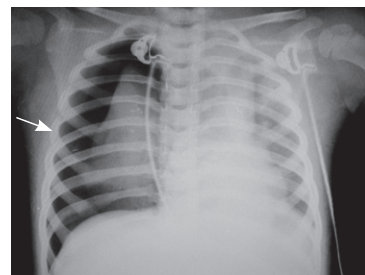


Fig. 4. Chest X-ray showing right pneumothorax.

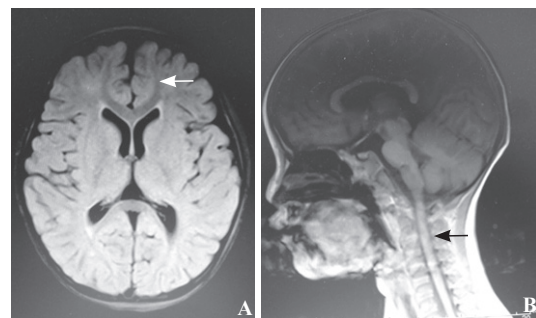


Fig. 5. Cranial (A) and spinal (B) MRI showing multiple abnormal patchy signals within the white matter of both cerebral hemispheres and a possible cervical spinal cord contusion.

was successfully removed on the same day. The child was then transferred to the rehabilitation ward for hyperbaric oxygen therapy. She was finally diagnosed with high fall injury; closed abdominal injury (stomach rupture, contusion, laceration of the liver and spleen, traumatic pancreatitis, and acute diffuse peritonitis); traumatic shock; closed head injury; cervical spinal cord contusion; fractures of the left ulna, tibia, and fibula; and multiple skin/soft tissue contusions. After 2 weeks of rehabilitation and hyperbaric oxygen therapy, her vision and left upper limb became normal.

Discussion

Fall-related injury is a common cause of trauma and one of the most common causes of accidental death. In general, falling from a height of >100 feet is considered a "nonsurvivable" injury.^[3] More attention should be paid to patients who survived a height fall because they may have sustained brain injury and internal organ injury from deceleration and impact and may present in shock.

Traumatic shock refers to trauma-induced systemic stress response, rapid decrease of effective circulating blood volume causing microcirculatory disorders, and multi-organ dysfunction syndrome. Reasonable and early fluid resuscitation and surgical control of bleeding are pivotal for patients with traumatic shock.^[4] In this patient, crystalloid and colloid resuscitation, administration of vasoactive drugs, and timely surgical repair and hemostasis gradually increased the BP to a normal level.

Unlike traffic accident injuries, fall-related injuries are mainly characterized by intracranial injuries, particularly in children^[5] because of their large head-to-body ratio and immature brain tissue. Impaction by an external force thus frequently leads to more severe brain injuries in children than in adults. The fall in this case was blocked by a neighbor's forearms, which may reduce the impact force. In addition, she fell on soft grass, and the left body landed on the ground; thus, neither intracranial hemorrhage nor skull fracture occurred.

After the first surgery, she quickly developed a deep coma. Spontaneous breathing ceased and she had a low GCS score of 3. A possible reason may be that the shear stress and impact force induced by the high fall caused brain stem or/and white matter injuries. According to the cranial MRI images, diffuse axonal injury was considered, the pathogenesis of which is associated with edema and axonal laceration, caused by the shear while falling. Protection of the brain from secondary injuries is essential to improve long-term neurologic outcomes.^[6] Because hyperventilation is potentially harmful to brain perfusion, we used mannitol to reduce the intracranial pressure and improve the cerebral hemodynamics and oxygenation for adequate cerebral blood supply. In addition, other interventions such as

mild hypothermia were employed for effective control of diffuse brain edema in the early stage^[7] and for recovery of consciousness.

During emergency treatment of fall-related injuries in children, rapid intubation, early resuscitation, and timely transfer to a qualified trauma center contribute to patient survival. A variety of factors, such as the impact of the falling height, quality of the impact surface, and position of the body relative to the impact surface, must be taken into account when designing rehabilitation strategies and assessing factors related to outcome.^[8]

In conclusion, this case illustrates that a child falling from extreme heights can occasionally be rescued. After emergent treatment, early neuroprotective strategies should be considered as soon as his or her clinical conditions stabilize.

Funding: This study was supported by grants from the Natural Science Foundation of Zhejiang Province, China (No. LY12H19006) and the Provincial Medical Science Foundation of Zhejiang Province, China (No. 2012KYB119).

Ethical approval: Not needed.

Competing interest: No benefits in any form have been received or will be received from any commercial party related directly or indirectly to the subject of this article.

Contributors: Yang ZH wrote the main body of the article under the supervision of Ye S. Zhang CM, Lou XF and Chen ZJ provided advices.

References

- 1 Marshall SW, Runyan CW, Yang J, Coyne-Beasley T, Waller AE, Johnson RM, et al. Prevalence of selected risk and protective factors of falls in the home. *Am J Prev Med* 2005;28:95-101.
- 2 Richter D, Hahn MP, Ostermann PA, Ekkernkamp A, Muhr G. Vertical deceleration injuries: a comparative study of the injury patterns of 101 patients after accidental and intentional falls. *Injury* 1996;27:655-659.
- 3 Lapostolle F, Gere C, Borron SW, Pétrovic T, Dallemagne F, Beruben A, et al. Prognostic factors in victims of falls from height. *Crit Care Med* 2005;33:1239-1242.
- 4 Spinella PC, Holcomb JB. Resuscitation and transfusion principles for traumatic hemorrhagic shock. *Blood Rev* 2009;23:231-240.
- 5 Harris VA, Rochette LM, Smith GA. Pediatric injuries attributable to falls from windows in the United States in 1990-2008. *Pediatric* 2011;128:455-462.
- 6 Koch JD, Kernie SG. Protecting the future: neuroprotective strategies in the pediatric intensive care unit. *Curr Opin Pediatr* 2011;23:275-280.
- 7 Lee HC, Chuang HC, Cho DY, Cheng KF, Lin PH, Chen CC. Applying cerebral hypothermia and brain oxygen monitoring in treating severe traumatic brain injury. *World Neurosurg* 2010;74:654-660.
- 8 Keenan HT, Bratton SL. Epidemiology and outcomes of pediatric traumatic brain injury. *Dev Neurosci* 2006;28:256-263.

Received October 30, 2011

Accepted after revision March 28, 2012