

# Clinical and pathological characteristics of Alagille syndrome in Chinese children

Jian-She Wang, Xiao-Hong Wang, Qi-Rong Zhu, Zhong-Lin Wang, Xi-Qi Hu, Shan Zheng  
Shanghai, China

**Background:** Alagille syndrome (AS) is regarded as the most common cause of chronic cholestasis in childhood associated with specific phenotypic features in western countries. This study was undertaken to investigate the significance of AS in Chinese children with chronic cholestasis and to describe its clinical and histological features.

**Methods:** From October 2004 to January 2007, 157 children who presented with conjugated jaundice from less than 3 months of age were admitted to a tertiary hospital in Shanghai. Investigations of the heart, spine, eyes and kidneys were conducted in 13 children who experienced prolonged cholestasis beyond 1 year of age after exclusion of biliary atresia and familial progressive intrahepatic cholestasis type 1 or 2. In patients with interlobular bile duct paucity, AS was diagnosed if 3 or more of the following 5 major features were present: cardiac murmur, posterior embryotoxon, butterfly-like vertebrae, renal abnormalities and characteristic faces. In patients without interlobular bile duct paucity or who did not receive liver biopsy, 4 or more features were required for the diagnosis.

**Results:** Of the 13 children, 6 were diagnosed with AS at ages ranging from 1 year and 7 months to 3 years and 11 months. Jaundice was noticed in early infancy and then pruritus developed in all the 6 patients, of whom 5 presented with acholic stool and 4 had been misdiagnosed as having presumed biliary atresia by hepatobiliary scintigraphy or laparoscopic cholangiography. Biochemical examinations demonstrated increased concentration of total bile acid and hyperlipidemia. Interlobular bile duct

paucity was demonstrated histologically in 5 patients who received liver biopsy. Vertebral abnormalities, heart murmur, characteristic faces and failure to thrive were found in all the 6 patients. Two patients had evidence of renal involvement. Micropenis, empty scrotum, and gall stone were seen in 1 patient.

**Conclusion:** AS is also an important cause of prolonged cholestasis in Chinese children. It is difficult to differentiate AS from biliary atresia. Liver biopsy and spine X-ray may be helpful in the early detection of AS.

*World J Pediatr* 2008;4(4):283-288

**Key words:** Alagille syndrome;  
biliary atresia;  
cholestasis

## Introduction

Alagille syndrome (AS) is an autosomal dominant disorder that affects multiple organ systems including the liver, heart, eyes, vertebrae, face, and kidneys.<sup>[1,2]</sup> Chronic cholestasis since birth is usually the most prominent clinical manifestation of AS. The prompt differentiation of AS from biliary atresia is usually of great difficulty.<sup>[3]</sup> Although it is generally regarded as the most common cause of chronic cholestasis in childhood associated with specific phenotypic features in western countries, AS has scarcely been reported in China.<sup>[4]</sup> To understand the clinical significance of AS in Chinese children, an investigation of AS manifestations has been conducted in children with prolonged cholestasis in our pediatric liver service recently and 6 cases have been identified.

## Methods

### Patients

From October 2004 to January 2007, 157 children including 111 males and 46 females, who presented with conjugated jaundice from less than 3 months of age were admitted to the Department of Infectious

**Author Affiliations:** The Center for Pediatric Liver diseases, Children's Hospital of Fudan University; The Department of Pediatrics, Shanghai Medical College of Fudan University (Wang JS, Wang XH, Zhu QR, Wang ZL, Zheng S); The Department of Pathology (Hu XQ), Shanghai Medical College of Fudan University, Shanghai 200032, China

**Corresponding Author:** Jian-She Wang, PhD, MD, Children's Hospital of Fudan University, 183 Fenglin Road, Shanghai 200032, China (Tel: +86-21-64160705; Fax: +86-21-64931901; Email: jshwang@shmu.edu.cn)

©2008, World J Pediatr. All rights reserved.

Diseases, Children's Hospital of Fudan University, a tertiary hospital in Shanghai for further investigation of their etiology. In this study, conjugated jaundice was defined as serum total bilirubin (TBil) exceeding 85  $\mu\text{mol/L}$  with a conjugated fraction of more than 15% of the total. On admission, 25 children, 12 males and 13 females, who experienced chronic cholestasis, were beyond 1 year of age. Of the 25 cases, 8 had biliary atresia after the Kasai procedure, 4 were presumed to have progressive intrahepatic cholestasis type 1 or 2 because of typical low gamma glutamyltranspeptidase (GGT, consistently less than 50 U/L), the remaining 13 cases were subjected to heart auscultation and cardiac echography, spine X-ray, posterior embryotoxon, kidney ultrasound, and liver biopsy. The study design conformed to the ethical guidelines of the 1975 Declaration of Helsinki and was approved by the Ethics Committee on Human Research of the Children's Hospital of Fudan University. Informed consent was obtained from the parents or guardians of the patients.

### Diagnostic criteria

According to the revised diagnostic criteria,<sup>[3]</sup> diagnosis was made by histological findings of interlobular bile ducts paucity with involvement of at least 3 of the 5 major abnormalities: cardiac murmur, eye abnormalities (posterior embryotoxon), butterfly-like vertebral anomalies, renal abnormalities and characteristic faces; or at least 4 of the 5 features if liver biopsy was not performed.

### Results

Six children met the diagnostic criteria of AS at ages ranging from 1 year and 7 months to 3 years and 11 months. They consisted of 3 males and 3 females with birth weight from 2750 g to 3500 g. The pregnancies of their mothers were normal except those mothers of cases 1 and 2, who reported a history of upper respiratory infection in the 3rd month of their pregnancy. The results of liver function tests of the parents were normal. The major abnormalities in the 6 patients who were diagnosed with AS are summarized in Table 1.

### Liver manifestations

Jaundice was the first noticeable presentation in all the 6 cases. In cases 1-4 and 6, jaundice was first noticed with acholic stool during the first week of life. In case 5, jaundice was first noticed with light yellow stool at 2 months of age.

Case 1 had been diagnosed as having presumed biliary atresia by laparoscopic cholangiography

performed in another tertiary children's hospital, but the Kasai procedure was refused by the parents. Cases 2-4 had been diagnosed as having presumed biliary atresia by no excretion of Tc-99m hydroxy iminodiacetic acid (HIDA) into the small intestine from the liver shown by 24-hour scintigraphy (HIDA scan) at the age of 1 to 5 months. Among them, case 2 received laparoscopic cholangiography at the age of 78 days, and narrow but patent bile duct system was demonstrated. The biliary system was rinsed in the patient. Case 5 received HIDA scan, demonstrating normal excretion of isotope into the small intestine at the age of 3 months. Case 6 was not specifically investigated except for some chologogues before he was referred to our hospital at the age of 3 years and 11 months.

Jaundice resolution along with growth was noticed in all the 6 cases. However, various degrees of pruritus appeared before the age of 1 year in all of them. In cases 4 and 5, icterus was not observed macroscopically at the age of 9 months and 11 months respectively, and the serum total bilirubin level decreased to the normal range at the age of 2 years and 3 months and 1 year and 7 months, respectively. In the other cases, jaundice was persistent and the serum total bilirubin level was above the upper normal limit all the time. High levels of total serum bile acid and gamma glutamyltranspeptidase were seen in all the cases. The biochemistry profile and the age at the last follow-up are shown in Table 2.

HIDA scan was performed again in cases 1, 3, and 4 at the age of 1 year and 6 months, 1 year and 11 months, and 7 months respectively. Delayed excretion was found in all these cases. Ultrasound examination revealed hepatomegaly in all the 6 cases, splenomegaly in cases 2-4, rough gallbladder wall in cases 1-3, and cholelithiasis in case 1. Ultrasound scan showed a neoplasm-like lesion in the borderline of the right and left lobes of the liver in case 2, but it was confirmed later as a focal fibrosis by CT and MRI. Dilated portal vein was seen in no case.

### Cardiac manifestations

There were no heart-related clinical symptoms such as cyanosis or recurrent pneumonia, but II-III/VI systolic ejection murmur was heard in the precordium. Chest X-ray showed slightly enlarged heart in case 1, probable congestive heart disease in case 3, and no obvious heart abnormalities in other cases. Cardiac echography showed atrial septum defect, intermediate peripheral pulmonary stenosis, and prolonged contraction of right ventriculus in case 1, patent ductus arteriosus, both left and right pulmonary arteries stenosis, and patent foramen ovale in case 2. Cases 3-6 were not subjected to cardiac echography.

### Skeleton manifestations

No macroscopic abnormality or dysfunction was found in the vertebral column or limbs, although abnormalities in vertebrae were demonstrated by X-ray. The main abnormalities shown by X-ray were butterfly-like vertebrae or central lucency. Vertebral abnormalities were usually found in thoracic vertebrae (T) in case 1 in T6, case 2 in T3-4, case 3 in T 7-9, case 4 in T4 and T6-10 (Fig. 1), case 5 in T4, T7 and T9, and case 6 in T4-9.

### Facial appearance

All the 6 cases had characteristic faces including prominent forehead, deep-set eyes with mild hypertelorism, pointed chin, and saddle shape nose with a bulbous tip. The combination of these features gave the face a triangular appearance. The lateral profile was flat with prominent ears (Fig. 2).

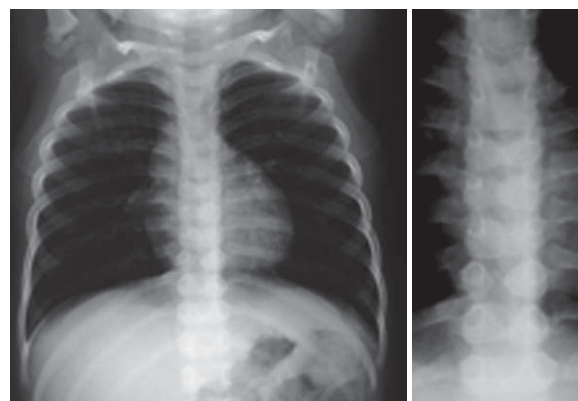
### Others

Skin scratching marks were seen in all the cases of different severity. Growth and development retardation, as the height and body weight below the lower third percentile of normal children and gross motor delay, was also seen in all the cases.

Small kidneys were demonstrated by ultrasound scan in cases 1 and 5, with significant azotemia in case 1. Small penis and undescended testicles were also found in case 1. Cytomegalovirus IgM was detected in cases 1, 4 and 5.

### Liver histopathological study

Cases 1-4 and 6 underwent needle liver biopsy at the ages of 1 year and 7 months, 3 years, 1 year and 11 months, 7 months, and 3 years and 11 months, respectively. The parenchyma structure was normal or nearly normal with no obvious hepatocyte degeneration or necrosis, but mild to moderate inflammation in the portal areas. Portal fibrosis was present in 4 of them. The most important and constant feature was the paucity of bile ducts. Interlobular bile ducts were totally absent in cases 1-3 and 6, with a significant reduction in the number of portal tracts in cases 1 and 6. In case 4,



**Fig. 1.** Spinal X-ray of Alagille syndrome. Vertebral arch defects in which the anterior arches of several dorsal vertebrae are not fused, resulting in a "butterfly-like" appearance. "butterfly" vertebrae seen in T4, T6-9, and central lucency in T10 in case 4.

**Table 1.** Major manifestations in accordance with Alagille syndrome

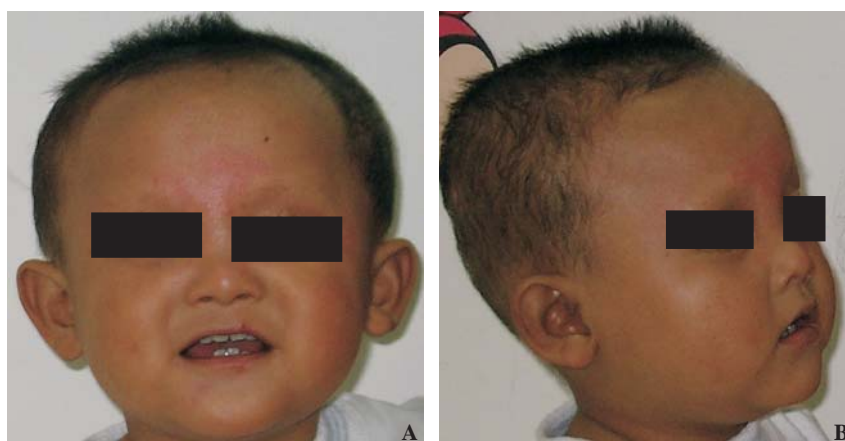Case No.	Interlobular bile duct paucity	Cholestasis	Cardiac murmur	Butterfly-like vertebrae	Characteristic face	Posterior embryotoxon	Kidney abnormalities
1	+	+	+	+	+	+	+
2	+	+	+	+	+	+	-
3	+	+	+	+	+	ND	-
4	+	+	+	+	+	+	-
5	ND	+	+	+	+	+	+
6	+	+	+	+	+	+	-

+: yes; -: no; ND: not done.

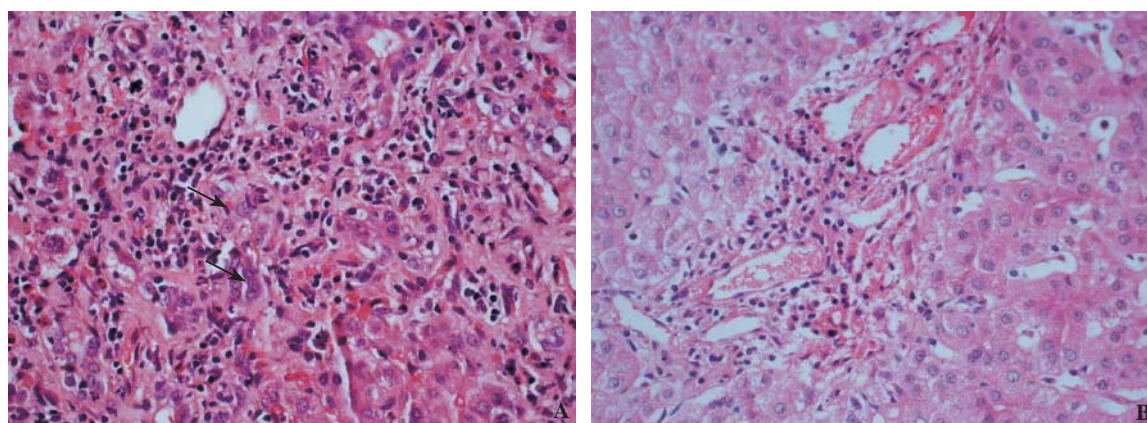
**Table 2.** The biochemical profile and the age of the patients at the last follow-up

Case No.	Age of last follow-up	TB/DB	ALT/AST	AKP/GGT	TBA	Tch/TG
1	1 y 7 mon	101/83	99/154	650/1127	346	5.3/2.3
2	5 y 3 mon	43/34	93/75	481/256	381	9.6/4.2
3	3 y	79/54	63/183	1053/975	54.5	8.8/3.2
4	4 y 1 mon	24/18	74/80	62/235	329	8.8/4.5
5	2 y 3 mon	15/11	80/60	423/213	121	8.7/1.6
6	3 y 11 mon	150/126	18/79	494/177	443	ND

Abbreviation (upper normal limit): TB: total bilirubin (17.1  $\mu\text{mol/L}$ ); DB: direct bilirubin (6  $\mu\text{mol/L}$ ); ALT: alanine aminotransferase (40 U/L); AST: aspartic transaminase (40 U/L); AKP: alkaline phosphatase (265 U/L); GGT:  $\gamma$ -glutamyl transferase (50 U/L); TBA: total bile acid (10  $\mu\text{mol/L}$ ); Tch: total cholesterol (5.9  $\mu\text{mol/L}$ ); TG: triglycerol (1.7  $\mu\text{mol/L}$ ); ND: not determined.



**Fig. 2.** Characteristic faces of Alagille syndrome. **A:** a child aged 1 year and 7 months with prominent forehead, deep-set eyes, mild hypertelorism, pointed chin, and saddle shape nose with a bulbous tip; **B:** the lateral profile was flat with prominent ears.



**Fig. 3.** The histopathological change of liver biopsy in case 2. **A:** Wedge liver biopsy specimen at 87 days, showing proliferation of bile ductules (arrows) within a portal area, and significant intracellular and canalicular cholestasis and significant portal inflammation, including lymphocytes in ductal epithelial cells (HE, original magnification  $\times 400$ ); **B:** needle biopsy specimen at 36 months, showing lack of ductal elements within the portal space, only mild inflammation, no significant cholestasis (HE, original magnification  $\times 400$ ).

the ratio of interlobular bile ducts to the number of the portal tract was reduced to 2/7. Liver specimens from needle biopsy or from exploratory laparotomy biopsy were available in case 2. Histological comparison found disappearance of the interlobular bile duct with inflammatory infiltration and improvement of portal fibrosis with time. Significant intracellular and canalicular cholestasis was seen in the wedge biopsy specimen at the age of 87 days, but not in the specimen of needle biopsy (Fig. 3).

### Management

Fat soluble vitamins including vitamin A, D, E and K were supplied with ursodeoxycholic acid on admission. Rifampin was given to case 2 to relieve pruritus. Itching improved obviously 1 week after the initiation of rifampin, but aggravated when the treatment was

stopped. This phenomenon repeated twice. After rifampin was given for the third time, the itching improved again.

### Discussion

Alagille syndrome, which was first recognized by Alagille and colleagues in 1969, was reported to be the most common cause of phenotypical chronic cholestasis in Western countries.<sup>[5,6]</sup> Recently, the syndrome has been increasingly reported in Asian population.<sup>[7,8]</sup> Although the incidence is unclear in Chinese, AS seems to be an important cause of chronic cholestasis as shown in our study.

### Clinical manifestations of AS

Most cases in this series manifested obstructive

jaundice, although the jaundice resolved in some children with appearance of pruritus. The patients whose jaundice disappeared may still manifest obvious itching. Significantly increased serum levels of total bile acid and gamma glutamyltranspeptidase with obvious hyperlipidemia as a whole are the main biochemical difference from other causes of chronic intrahepatic cholestasis, such as those caused by progressive familial intrahepatic cholestasis types 1 and 2, and various defects in bile salt synthesis.

Heart murmur is the second most common manifestation of AS,<sup>[3]</sup> although most patients do not present with any clinical symptoms. Because echocardiography may not well display the peripheral pulmonary arteries, cardioangiography or MRI should be done to investigate the blood vessel system before the correction of inner-cardiac abnormalities. Intracranial vessel abnormalities and other vascular anomalies have been reported as a main cause of mortality in AS recently.<sup>[9]</sup>

Characteristic faces may be recognized in early infancy and it can be more easily found as growing up. Usually the forehead looks more prominent in infancy with pointed chin. In older children, the pointed chin is more prominent with the forehead not as prominent as that in the infancy. Facial features are of diagnostic value to AS.<sup>[10]</sup>

Renal abnormalities occur in 40%-50% of patients with AS including structural, functional, and acquired renal disorders.<sup>[11]</sup> Renal disease has been considered one of the "major" criteria for the diagnosis of AS recently,<sup>[3]</sup> and it was noticed in one third of our cases.

### Histopathological characteristics and diagnosis of AS

The paucity of intrahepatic bile ducts in liver biopsy is traditionally regarded as the most important consistent feature of AS. However, in infants less than 6 months old, adequate numbers of interlobular bile ducts may be present.<sup>[12]</sup> Biopsy at 87 days and 3 years in case 2 demonstrated that bile ductules proliferated in early infancy but disappeared gradually for unknown reasons, which increases the difficulty of diagnosis of AS in early infancy. The most interesting aspect of AS is that the end-stage liver diseases do not develop in most cases along with the disappearance of intrahepatic bile ducts.<sup>[13]</sup> Just as illustrated in case 2, intrahepatic cholestasis may resolve significantly though the interlobular bile ducts disappeared with time.

In recent years, 94% of AS cases have been traced to mutations in *JAG1* using various molecular techniques.<sup>[14]</sup> Genetic studies may play an important role in the diagnosis of clinical suspected cases in the future although the diagnosis of proband is still dependent on clinical features currently.<sup>[3,14]</sup>

AS is an autosomal dominant disorder with highly variable expressivity. None of the parents in this series had clinical manifestations, although posterior embryotoxon was found in the father of case 4, heart murmur in the mother, mother's brother, and mother's father of case 5, and similar facial features in the father of case 6. Therefore, similar cases in the family may do some but little help to the establishment of the diagnosis of AS in the proband.

### Differential diagnosis and management

It was very important to differentiate AS from other disorders with cholestasis, especially biliary atresia in consideration of that 4 of our 6 cases had been misdiagnosed as presumed biliary atresia by laparoscopic cholangiography or isotope scintigraphy. Biliary atresia should be treated operatively as early as possible, but if AS is misdiagnosed, operation may do harm to the prognosis as reported.<sup>[6]</sup> Although multiple organ systems may be involved in AS, the abnormalities of spinal vertebrae or eyes are usually not clinically significant. Characteristic face may not be distinct in early infancy. All these make the differential diagnosis very difficult. Some patients with AS have been misdiagnosed as having biliary atresia and the Kaisai procedure was performed.<sup>[13]</sup> Liver biopsy may be helpful in the differential diagnosis. In biliary atresia, bile duct proliferation is one of the typical histological manifestations. Although bile duct paucity may not exist in early stage of AS, bile duct proliferation is rare.<sup>[3,12]</sup> More importantly, the proliferated bile duct is usually located at the periphery of the bile tract, and the interlobular bile duct is close to the central vein. Traditionally, pathologists pay less attention to the interlobular bile duct, so request regarding the relevant information should be made to them in advance.

The management of AS is symptomatic or supportive. Liver transplantation may be needed when end-stage liver diseases or severe pruritus develop. However, itching may be less significant as the patients grow up. Besides, patients with AS generally have growth retardation and hyperlipidemia. These problems are challenging to the long-term management of AS.

In this study thorough investigations were not performed in the patients less than 1 year old and only those with relatively severe jaundice were referred. Hence, data were not used to estimate the prevalence of AS in this population. Moreover, AS has never been regarded as a significant cause of infantile cholestasis in the mainland of China and thus no relevant investigations are available as routine screening. In fact, selective screening may be cost-effective in China. With the increasing knowledge about AS, more

AS cases have been identified in our practice, including those cases at the young age. We conclude that AS is a cause of chronic cholestasis in Chinese children and early investigation is required to distinguish it from biliary atresia. Histological examination of liver biopsy specimens and X-ray of spinal column may contribute to a correct diagnosis of the disease. Long-term management of the syndrome is still challenging.

**Funding:** This paper was supported by a grant (No. 30672257, the significance of BSEP gene mutation in nonprogressive infantile intrahepatic cholestasis, 2007,1-2009,12) from the National Natural Science Foundation of China and a grant from the Children's Hospital of Fudan University. The authors appreciate the cooperation of participating patients and their family.

**Ethical approval:** This study was approved by the Ethics Committee on Human Research of the Children's Hospital of Fudan University.

**Competing interest:** None.

**Contributors:** Wang JS contributed to study design, data collection, data analysis, and writing of the paper; Wang XH contributed to data collection and writing of the paper; Zhu QR contributed to study design, data analysis, and writing of the paper; Wang ZL contributed to follow-up of the patients and data collection; Hu XQ contributed to pathological study, and writing of the paper; and Zheng S contributed to data collection and writing of the paper.

## References

- Alagille D, Odievre M, Gautier M, Dommergues JP. Hepatic ductular hypoplasia associated with characteristic facies, vertebral malformations, retarded physical, mental, and sexual development, and cardiac murmur. *J Pediatr* 1975;86:63-71.
- Alagille D, Estrada A, Hadchouel M, Gautier M, Odièvre M, Dommergues JP. Syndromic paucity of interlobular bile ducts (Alagille syndrome or arteriohepatic dysplasia): review of 80 cases. *J Pediatr* 1987;110:195-200.
- Piccoli DA. Alagille syndrome. In: Suchy FJ, Sokal RJ, Balistreri WF, eds. *Liver disease in children*, 2nd ed. Philadelphia: Lippincott Williams & Wilkins, 2001: 327-342.
- Fan ST, Lo CM, Chan KL, Lo R, Saing H, Wei W, et al. Liver transplantation—perspective from Hong Kong. *Hepatogastroenterology* 1996;43:893-897.
- Balistreri WF, Bezerra JA, Jansen P, Karpen SJ, Shneider BL, Suchy FJ. Intrahepatic cholestasis: summary of an American Association for the Study of Liver Diseases single-topic conference. *Hepatology* 2005;42:222-235.
- Hoffenberg EJ, Narkewicz MR, Sondheimer JM, Smith DJ, Silverman A, Sokol RJ. Outcome of syndromic paucity of interlobular bile ducts (Alagille syndrome) with onset of cholestasis in infancy. *J Pediatr* 1995;127:220-224.
- Kim B, Park SH, Yang HR, Seo JK, Kim WS, Chi JG. Hepatocellular carcinoma occurring in Alagille syndrome. *Pathol Res Pract* 2005;201:55-60.
- Kasahara M, Kiuchi T, Inomata Y, Uryuhara K, Sakamoto S, Ito T, et al. Living-related liver transplantation for Alagille syndrome. *Transplantation* 2003;75:2147-2150.
- Kamath BM, Spinner NB, Emerick KM, Chudley AE, Booth C, Piccoli DA, et al. Vascular anomalies in Alagille syndrome: a significant cause of morbidity and mortality. *Circulation* 2004;109:1354-1358.
- Kamath BM, Loomes KM, Oakey RJ, Emerick KE, Conversano T, Spinner NB, et al. Facial features in Alagille syndrome: specific or cholestasis facies? *Am J Med Genet* 2002;112:163-170.
- Tolia V, Dubois RS, Watts FB, Perrin E. Renal abnormalities in paucity of interlobular bile ducts. *J Pediatr Gastroenterol Nutr* 1987;6:971-976.
- Hashida Y, Yunis EJ. Syndromic paucity of interlobular bile ducts: hepatic histopathology of the early and endstage liver. *Pediatr Pathol* 1988;8:1-15.
- Lykavieris P, Hadchouel M, Chardot C, Bernard O. Outcome of liver disease in children with Alagille syndrome: a study of 163 patients. *Gut* 2001;49:431-435.
- Warthen DM, Moore EC, Kamath BM, Morrisette JJ, Sanchez P, Piccoli DA, et al. Jagged1 (JAG1) mutations in Alagille syndrome: increasing the mutation detection rate. *Hum Mutat* 2006;27:436-443.

Received April 30, 2008

Accepted after revision August 19, 2008